

The AAO

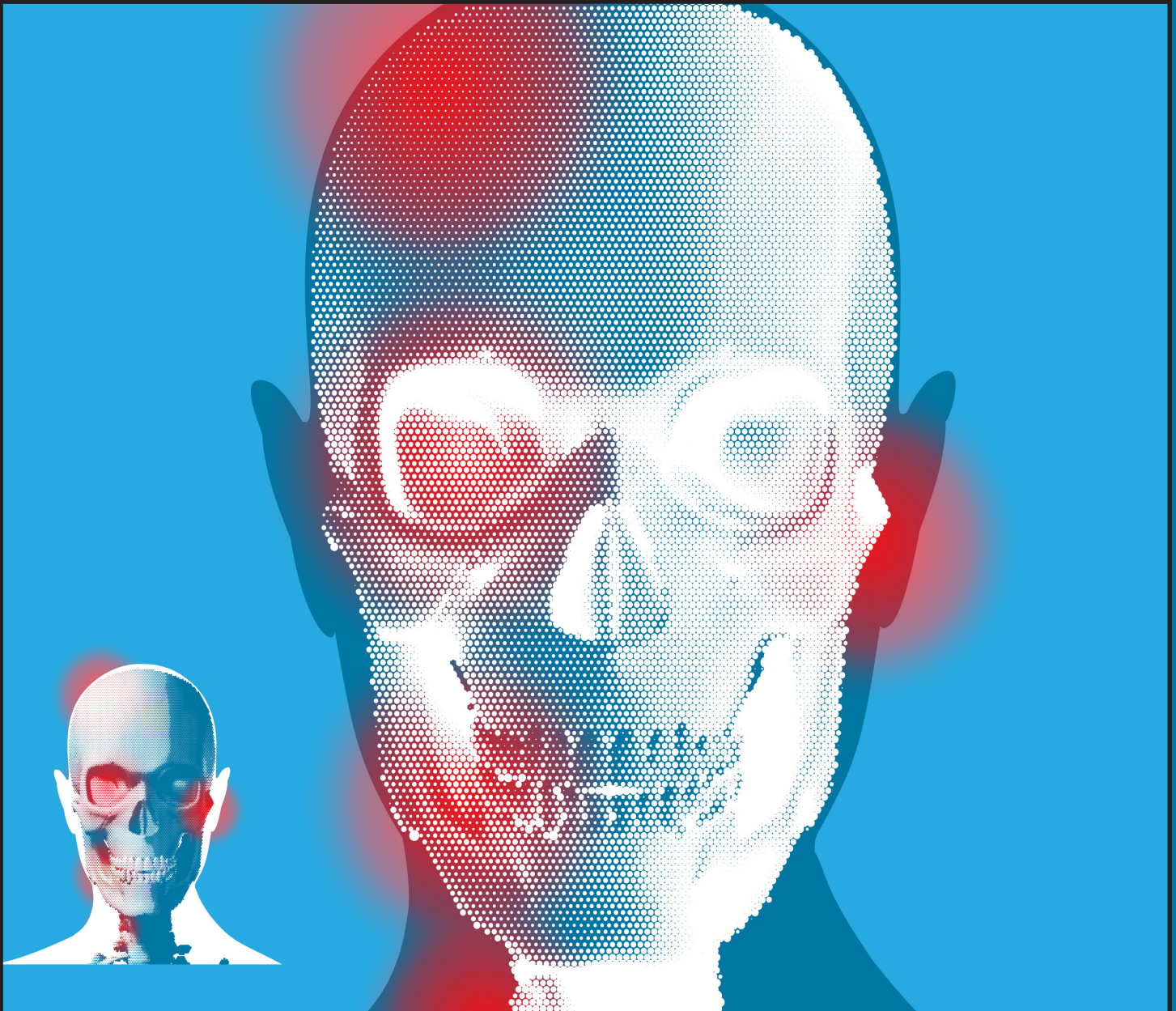
FORUM FOR OSTEOPATHIC THOUGHT

# JOURNAL

Official Publication of the American Academy of Osteopathy •

TRADITION SHAPES THE FUTURE

VOLUME 26 • NUMBER 1 • MARCH 2016



*In the case study that starts on page 17, Karen Teten Snider, DO, FAAO, describes how osteopathic manipulative treatment provided immediate relief for a patient with acute dental pain.*

# The American Academy of Osteopathy is your voice...

*in teaching, promoting, and researching the science, art, and philosophy of osteopathic medicine, with the goal of integrating osteopathic principles and osteopathic manipulative treatment in patient care.*

If you are not already a member of the American Academy of Osteopathy (AAO), the AAO Membership Committee invites you to [join the Academy](#) as a 2015-16 member. The AAO is your professional organization. It fosters the core principles that led you to become a doctor of osteopathic medicine.

For \$5.27 a week (less than the price of a large specialty coffee at your favorite coffee shop) or just 75 cents a day (less than the cost of a bottle of water), you can become a member of the professional specialty organization dedicated to you and osteopathic manipulative medicine (OMM).

Your membership dues provide you with:

- a national advocate for OMM, both within the profession and with health care policy-makers and third-party payers.
- a champion that is monitoring closely and responding rapidly to the standards being developed for the single accreditation system for graduate medical education.
- referrals of patients through the “Find a Physician” tool both on the AAO website and at the [FindOMM.org](#) URL, as well as from calls to the AAO office.
- discounts on continuing medical education at the AAO’s annual Convocation and its weekend courses.
- automatic acceptance of AAO-sponsored courses by the American Osteopathic Board of Neuromusculoskeletal Medicine, the only certifying board for manual medicine in the world today.

- networking opportunities with peers.
- discounts on books in the AAO’s [online store](#).
- complimentary subscription to *The AAO Journal*, published electronically 4 times annually.
- complimentary subscription to the online *AAO Member News*, published 8 times annually.
- weekly *OsteoBlast* e-newsletters, featuring research on manual medicine from peer-reviewed journals around the world.
- practice promotion materials, such as the AAO-supported “American Health Front!” segment on OMM.
- discounts on advertising in AAO publications, on the AAO website, and on materials for the AAO’s Convocation.
- the fellow designation of FAAO, which recognizes DOs for promoting OMM through teaching, writing, and professional service and which is the only earned fellowship in the osteopathic medical profession.
- promotion and grant support of research on the efficacy of OMM.
- support for the future of the profession through the Student American Academy of Osteopathy, the National Undergraduate Fellows Association, and the Postgraduate American Academy of Osteopathy.

If you have any questions regarding membership or membership renewal, contact AAO Membership Liaison Susan Lightle at [SLightle@academyofosteopathy.org](mailto:SLightle@academyofosteopathy.org) or at (317) 879-1881, ext. 217.



**BURRELL COLLEGE**  
OF OSTEOPATHIC MEDICINE  
at  
New Mexico State University

## You are invited to join a Team of Leaders Committed to Bringing Osteopathic Medicine to New Mexico

Burrell College of Osteopathic Medicine in Las Cruces, New Mexico is looking for a full-time faculty member. The OMM Department is seeking a visionary, creative, hardworking NMM or FM/OMM pioneer to bring OPP/OMM to New Mexico and the surrounding region.

### Be part of a team with the following opportunities:

- Leadership in the OMM Department
- Development and course direction of all four years of a fully integrated pre-doctoral OMM curriculum
- Development of pre-approved inpatient OMT services at local hospitals
- Leadership of a newly approved NMM Residency Program



Photograph by Heather Kelly

Las Cruces is located in Southern New Mexico at the base of the Organ Mountains in a region known for temperate weather, outdoor activities and a beautiful high desert landscape.

### Competitive salary and benefits

For further information please contact:

**Claire M. Galin, DO**

Assistant Dean for Osteopathic Integration  
Burrell College of Osteopathic Medicine

Email: [cgalin@bcomnm.org](mailto:cgalin@bcomnm.org)

Office phone: (575) 674-2304

At Convo: text to (505) 321-5283



3500 DePauw Blvd, Suite 1100  
 Indianapolis, IN 46268-1136  
 (317) 879-1881 • fax: (317) 879-0563  
[editoraaoj@gmail.com](mailto:editoraaoj@gmail.com)  
[www.academyofosteopathy.org](http://www.academyofosteopathy.org)

THE AAO FORUM FOR OSTEOPATHIC THOUGHT  
**JOURNAL**  
 Official Publication of the American Academy of Osteopathy®  
 TRADITION SHAPES THE FUTURE • VOLUME 26 • NUMBER 1 • MARCH 2016  
*The mission of the American Academy of Osteopathy is to teach, advocate, and research the science, art, and philosophy of osteopathic medicine, emphasizing the integration of osteopathic principles, practices, and manipulative treatment in patient care.*

**The AAO Journal**

Brian E. Kaufman, DO, FACOI, FACP . . . . . Scientific editor  
 Katherine A. Worden, DO, MS . . . . . Associate editor  
 Raymond J. Hruby, DO, FAAODist . . . Scientific editor emeritus  
 Lauren Good . . . . . Managing editor

**AAO Publications Committee**

Hollis H. King, DO, PhD, FAAO, chair	Raymond J. Hruby, DO, MS, FAAODist
William J. Garrity, DO, vice chair	Brian E. Kaufman, DO, FACOI, FACP
Claire M. Galin, DO	Hallie J. Robbins, DO
Edward Keim Goering, DO	Katherine A. Worden, DO, MS
Stephen I. Goldman, DO, FAAO, FAOASM	Richard G. Schuster, DO, Board of Trustees' liaison

**American Academy of Osteopathy**

Doris B. Newman, DO, FAAO . . . . . President  
 Laura E. Griffin, DO, FAAO . . . . . President-elect  
 Sherri L. Quarles. . . . . Interim executive director

*The AAO Journal* is the official publication of the American Academy of Osteopathy. Issues are published 4 times a year.

*The AAO Journal* is not responsible for statements made by any contributor. Opinions expressed in *The AAO Journal* are those of the authors and do not necessarily reflect viewpoints of the editors or official policy of the American Academy of Osteopathy or the institutions with which the authors are affiliated, unless specified.

Although all advertising is expected to conform to ethical medical standards, acceptance does not imply endorsement by this journal or by the American Academy of Osteopathy.

Subscription rate for AAO nonmembers: \$60 per year.  
 To subscribe, contact AAO Publications Liaison Lauren Good at [LGood@academyofosteopathy.org](mailto:LGood@academyofosteopathy.org).

Send all address changes to [SLightle@academyofosteopathy.org](mailto:SLightle@academyofosteopathy.org).

ISSN 2375-5717 (online) ISSN 2375-5776 (print)

**On the cover:** iStock ©iMrSquid/23075930

**EDITORIAL**

View From the Pyramids..... 5  
*Brian E. Kaufman, DO, FACOI, FACP*

**SPECIAL COMMUNICATION**

Somatic Dysfunction: A Principled Approach  
 to Diagnosis and the Selection of OMT Modalities.....7  
*Raymond J. Hruby, DO, MS, FAAODist*

**CASE REPORT**

The Use of Osteopathic Manipulative Treatment  
 for Acute Dental Pain: A Case Report ..... 17  
*Karen Teten Snider, DO, FAAO*

**REGULAR FEATURES**

AAO Calendar of Events ..... 4  
 CME Certification of Home Study..... 25  
 Component Society Calendar of Events ..... 28

The advertising rates listed below are for *The AAO Journal*, the official peer-reviewed publication of the American Academy of Osteopathy (AAO). AAO members and AAO component societies are entitled to a 20% discount on advertising in this journal. Call the AAO at (317) 879-1881, ext. 211, for more information.

2016 Advertising Rates per Placement			
	Placed 1 time	Placed 2 times	Placed 4 times
Full page (7.5" x 9.5")	\$600	\$570	\$540
One-half page (7.5" x 4.5")	\$400	\$380	\$360
One-third page (2.25" x 9.5")	\$300	\$285	\$270
Quarter page (3.5" x 4.5")	\$200	\$190	\$180
Classified	\$1 per 7 characters, spaces not included		



# AAO Calendar of Events



Mark your calendar for these upcoming Academy meetings and educational courses.

## 2016

March 15	Committee on Fellowship in the AAO's meeting, 8 a.m. to 5 p.m. Eastern time—Rosen Shingle Creek, Orlando, Florida	March 18	AAO Postdoctoral Training Committee's meeting, 2:30 to 3:30 p.m. Eastern time—Rosen Shingle Creek, Orlando, Florida
March 15	AAO Education Committee's meeting, 6 to 8 p.m. Eastern time—Rosen Shingle Creek, Orlando, Florida	March 19	AAO Student Academies Committee's meeting, 6:30 to 8 a.m. Eastern time—Rosen Shingle Creek, Orlando, Florida
March 16	AAO Board of Trustees' meeting, 8 a.m. to noon Eastern time—Rosen Shingle Creek, Orlando, Florida (also see March 19 listing)	March 19	AAO Website Task Force update, 6:30 to 8 a.m. Eastern time—Rosen Shingle Creek, Orlando, Florida
March 16	AAO Board of Governors' meeting, 1 to 5 p.m. Eastern time—Rosen Shingle Creek, Orlando, Florida	March 19	AAO Board of Trustees' meeting, 11 a.m. to 2 p.m. Eastern time—Rosen Shingle Creek, Orlando, Florida (also see March 16 listing)
March 16	AAO Investment Committee's meeting, immediately following Board of Governors' meeting—Rosen Shingle Creek, Orlando, Florida	March 20	Post-Convocation—Residency Program Directors' Workshop—Michael P. Rowane, DO, FAAO, course director—Rosen Shingle Creek, Orlando, Florida
March 16-20	AAO Convocation— <a href="#">Somatic Dysfunction and Emotional Well-being: An Osteopathic Approach to Mental Health</a> —Millicent King Channell, DO, FAAO, program chair—Rosen Shingle Creek, Orlando, Florida	April 29–May 1	<a href="#">Fulford's Basic Percussion Hammer</a> —Richard W. Koss, DO, course director—University of North Texas Health Science Center Texas College of Osteopathic Medicine in Fort Worth
March 17	AAO's annual business meeting and luncheon, 11:45 a.m. to 2:15 p.m. Eastern time—Rosen Shingle Creek, Orlando, Florida	June 16-19	<a href="#">Introduction to Osteopathic Manipulative Medicine</a> —Lisa Ann DeStefano, DO, course director—University of North Texas Health Science Center Texas College of Osteopathic Medicine in Fort Worth (This course is being supported in part by the AAO's Samuel V. Robuck Fund.)
March 18	AAO Louisa Burns Osteopathic Research Committee's meeting, 6:30 to 8 a.m. Eastern time—Rosen Shingle Creek, Orlando, Florida	Sept. 17-19	AAO at OMED: Osteopathic Neuromusculoskeletal Medicine in the 21st Century—Daniel G. Williams, DO, program chair—Anaheim (California) Convention Center
March 18	AAO Osteopathic Education Service Committee's meeting, 12:30 to 2:30 p.m. Eastern time—Rosen Shingle Creek, Orlando, Florida	Oct. 21-23	What's the Point? Multi-faceted Clinical Approaches to Viscerosomatic Reflexes—Michael L. Kuchera, DO, FAAO, course director—Midwestern University/Arizona College of Osteopathic Medicine in Glendale
March 18	AAO Osteopathic Medical Economics Committee's meeting, 12:30 to 2:30 p.m. Eastern time—Rosen Shingle Creek, Orlando, Florida	Dec. 2-4	Fulford's Advanced Percussion Hammer—Richard W. Koss, course director—University of North Texas Health Science Center Texas College of Osteopathic Medicine in Fort Worth
March 18	AAO Postdoctoral Standards and Accreditation Committee's meeting, 12:30 to 2:30 p.m. Eastern time—Rosen Shingle Creek, Orlando, Florida	Dec. 9-11	Arbuckle course—Kenneth J. Lossing, DO, course director—Midwestern University/Arizona College of Osteopathic Medicine in Glendale
March 18	AAO Publications Committee's meeting, 12:30 to 2:30 p.m. Eastern time—Rosen Shingle Creek, Orlando, Florida		



# View From the Pyramids

AAOJ Scientific Editor Brian E. Kaufman, DO, FACOI, FACP

EDITORIAL

The publishing of the March issue of *The AAO Journal* means that it is time for the AAO's Convocation. This is the annual pilgrimage when we flock together to exchange ideas, socialize, and reaffirm our love of osteopathic medicine. There is a reconnection with the osteopathic family, and we become infused with a sense of purpose and new techniques to integrate into our daily practice. No matter how many years I have gone, I always feel renewed upon my return.

Many important things happen at Convocation. One of these is the annual business meeting. We elect our colleagues to positions in order to help our cause. We have opportunities at the meeting to influence the direction and goals of our profession. This is one of the best ways to spend your lunchtime. At some of the previous business meetings I have witnessed debates, humor, and even marriage proposals (she said yes).

There are other groups that promote osteopathy and osteopathic manipulative treatment (OMT), and while this reassures us and enhances our profession, the American Academy of Osteopathy is the organization that *holds integrating osteopathic principles and practice (OPP) and OMT into patient care* as its primary mission. Our effectiveness is proportional to our level of participation. It is our collective voice that moves mountains and brings mighty foes


to the ground. There is an exponential increase in both how far and how fast we achieve our ends, the more of us that are involved. Together, we can assure that OPP has prominence in modern medicine and that OMT retains fair reimbursement.

For those who agree but do not speak up, who believe but do not advocate, and who want change but do not participate, I implore the following: Do not presume that your colleagues who volunteer their time, energy, and effort do so because they have no other use for them, but rather because of the knowledge that no one else will. Do not spend each day tending to your patients while lamenting the erosion of medicine, believing that the solution is being sought by others, but rather take it upon yourself to get involved, join a committee, submit research, write an article, disagree with me but most importantly, take a stance and let the powers that be know you are not happy with the status quo and will not passively accept the changes being forced upon you.

I look forward to seeing you all at Convocation. ■



Find publications by 2016 Convocation speakers, Academy members and more. Visit the Academy's online store at [www.academyofosteopathy.org](http://www.academyofosteopathy.org) or download the [book order form](#).



AAO members receive a 10% discount off listed prices.

# FULFORD'S BASIC PERCUSSION HAMMER

April 29–May 1, 2016 • University of North Texas Health Science Center  
Texas College of Osteopathic Medicine in Fort Worth

## Course Description

Based on the work of the late Robert C. Fulford, DO, this course introduces Dr. Fulford's concepts of vibration, love and breath as they relate to osteopathic philosophy and practice.

Strongly influenced by Andrew Taylor Still, MD, DO, and William Garner Sutherland, DO, Dr. Fulford emphasized how the energy of the body affects the physiology of the body. He was a proponent of the percussion hammer, which sends oscillating energy waves through the body to encourage healing.

Attendees will learn about Dr. Fulford's life and practice, and they will come to understand how life energy, fascia and piezoelectricity affect anatomy.

By the end of the course, attendees will be able to evaluate their patients, diagnose dysfunctions and apply vibratory treatment following Dr. Fulford's teachings on the percussion hammer.

## Prerequisite

Attendees must have completed a 40-hour introductory cranial course approved by The Osteopathic Cranial Academy or undergone equivalent training as determined acceptable by the course director.

## Course Times

Friday and Saturday from 8 a.m. to 6 p.m.

Sunday from 9 a.m. to 3 p.m.

## Meal Information

Breakfast and lunch will be provided each day. Please contact the Academy with special dietary needs at (317) 879-1881, ext. 220, or [EventPlanner@academyofosteopathy.org](mailto:EventPlanner@academyofosteopathy.org).

## Continuing Medical Education

22 credits of NMM- and FP-specific AOA Category 1-A CME anticipated.

## Course Location

University of North Texas Health Science Center  
Texas College of Osteopathic Medicine  
3500 Camp Bowie Blvd.  
Fort Worth, TX 76107



## Course Director

When **Richard W. Koss, DO**, completed his undergraduate degree at Springfield College in Massachusetts, he planned to teach physical education, but an encounter with Bertha Miller, DO, changed his focus to osteopathic medicine.

In 1982, Dr. Koss graduated from what is now the A.T. Still University-Kirkville College of Osteopathic Medicine (ATSU-KCOM) in Missouri, after which he served in the U.S. Air Force Medical Corps for four years as a general medical officer, first at McChord Air Force Base near Tacoma, Washington, and then at Robins Air Force Base near Warner Robins, Georgia.

Dr. Koss first attended a percussion course taught by Robert C. Fulford, DO, in 1987 when Dr. Koss was a resident in osteopathic manipulative medicine at ATSU-KCOM. Two years later, Dr. Fulford invited Dr. Koss to be a table trainer for a percussion course. Dr. Koss continued to assist Dr. Fulford until the latter's death in 1997.

## Travel Arrangements

Contact Tina Callahan of Globally Yours Travel at (800) 274-5975 or [globallyyourstravel@cox.net](mailto:globallyyourstravel@cox.net).

Registration Fees	By March 28, 2016	After March 28, 2016
Academy member in practice*	\$914	\$1,064
Resident or intern member	\$714	\$864
Student member	\$514	\$664
Nonmember practicing DO or other health care professional	\$1,114	\$1,264
Nonmember resident or intern	\$914	\$1,064
Nonmember student	\$714	\$864

\* The AAO's associate members, international affiliates and supporter members are entitled to register at the same fees as full members.

## Registration Form

### Fulford's Basic Percussion Hammer

April 29–May 1, 2016

Name: \_\_\_\_\_ AOA No.: \_\_\_\_\_

Nickname for badge: \_\_\_\_\_

Street address: \_\_\_\_\_

City: \_\_\_\_\_ State: \_\_\_\_\_ ZIP: \_\_\_\_\_

Phone: \_\_\_\_\_ Fax: \_\_\_\_\_

Email: \_\_\_\_\_

- I am a practicing health care professional.
- I am a resident or intern.
- I am an osteopathic or allopathic medical student.
- I meet the course prerequisite.

The AAO accepts check, Visa, MasterCard and Discover payments in U.S. dollars. The AAO does not accept American Express.

Credit card No.: \_\_\_\_\_

Cardholder's name: \_\_\_\_\_

Expiration date: \_\_\_\_\_ 3-digit CVV No.: \_\_\_\_\_

Billing address (if different): \_\_\_\_\_

I hereby authorize the American Academy of Osteopathy to charge the above credit card for the amount of the course registration.

Signature: \_\_\_\_\_

Click here to view the [AAO's cancellation and refund policy](#).

Click here to view the [AAO's photo release statement](#).



Register online at [www.academyofosteopathy.org](http://www.academyofosteopathy.org), or submit this registration form and your payment by email to [EventPlanner@academyofosteopathy.org](mailto:EventPlanner@academyofosteopathy.org); by mail to the American Academy of Osteopathy, 3500 DePauw Blvd., Suite 1100, Indianapolis, IN 46268-1136; or by fax at (317) 879-0563.



# Somatic Dysfunction: A Principled Approach to Diagnosis and the Selection of OMT Modalities

Raymond J. Hruby, DO, MS, FAAODist

SPECIAL COMMUNICATION

## Introduction

It is well established within the osteopathic medical profession that our founder, Andrew Taylor Still, MD, DO, did not write technique manuals.<sup>1</sup> He did not provide detailed descriptions for performing osteopathic structural examinations (OSE), nor did he provide step-by-step instructions for selecting and performing osteopathic manipulative techniques. Instead, he avoided such approaches, admonishing his students to first be thoroughly knowledgeable about normal human anatomy and physiology, and thus be able to more easily recognize when abnormalities are present. In short, knowledge of which body structures demonstrated “anatomical obstructions” would lead to an understanding of the resulting “physiologic discord.” In turn, this would lead to the correct diagnosis of the patient’s condition and the selection of treatment approaches most likely to be successful.

In the case of structural diagnosis and manipulative treatment, Still was confident that this approach would allow the osteopathic physician to design rational treatments and apply the most appropriate maneuvers and activating forces, resulting in the restoration of normal structural relationships and improvement in physiologic function, facilitating the patient’s return to a state of health and wellness.

With this in mind, this article proposes that osteopathic physicians (DOs) can use their knowledge of the anatomy, physiology, and biomechanics of specific musculoskeletal tissues and structures to rationally establish the presence of somatic dysfunction. Furthermore, DOs can recognize which musculoskeletal elements (such as bone, joint capsule, muscles, ligaments, and so on) are most predominantly involved. Using their knowledge of functional anatomy, physiology, and biomechanics, DOs can then more accurately judge what types of manual approaches and activating forces will be most successful in alleviating the patient’s somatic dysfunctions. DOs also use knowledge of osteopathic manipulative treatment (OMT) to judge which modalities would be most appropriate. The result will be a more accurate selection of OMT modalities that will prove to be more successful in re-establishing optimal structure-function relationships for any given patient.

From the Western University of Health Sciences College of Osteopathic Medicine of the Pacific (WesternU/COMP) in Pomona, California.

Financial disclosure: none reported.

Correspondence address:

Raymond J. Hruby, DO, MS, FAAODist  
Department of OMM  
309 E. Second St.  
Pomona, CA 91766-1854  
(909) 469-5289  
[RHruby@westernu.edu](mailto:RHruby@westernu.edu)

Submitted for publication October 7, 2015; final revision received January 28, 2016; accepted for publication March 3, 2016.

Board certified in family medicine and in neuromusculoskeletal medicine and osteopathic manipulative medicine (NMM-OMM), Dr Hruby was the 1990-91 president of the Academy, and he is editor emeritus of *The AAO Journal*. In 2015, Dr Hruby was named a fellow of distinction of the AAO.

Dr Hruby has been a professor of osteopathic manipulative medicine (OMM) and family medicine at WesternU/COMP for 16 years. He also has chaired the Department of OMM there.

In addition to his DO degree, Dr Hruby holds a bachelor’s degree in psychology and a master’s degree in computer science.

## Tissues and Structures Associated With Somatic Dysfunction

Somatic dysfunction is defined as “impaired or altered function of related components of the somatic (body framework) system: skeletal, arthrodiagonal and myofascial structures, and their related vas-

*(continued on page 8)*

(continued from page 7)

cular, lymphatic, and neural elements.”<sup>2</sup> Put another way, somatic dysfunction may be viewed as restricted motion of musculoskeletal structures, which in turn may compromise related arterial, venous, lymphatic and neural structures, leading to abnormal physiologic functions. When DOs palpate for somatic dysfunction, they are palpating specific musculoskeletal tissues and structures: bone, joint capsule, cartilage, ligament, tendon, muscle, and fascia. DOs palpate for certain characteristics (Tissue texture abnormalities, Asymmetry, Restriction of motion, and Tenderness—commonly referred to by the acronym TART) that indicate the presence of somatic dysfunction.

The above-mentioned musculoskeletal tissues and structures have at least 1 commonality among them: they all arise from the same embryologic tissue, namely mesenchyme (see Figure 1). Mesenchyme is the stem tissue of all the connective tissues of the body. Connective tissues have cells and an extracellular matrix: In many types of connective tissue, the matrix-secreting cells are called fibroblasts. Frequently, an abundance of other cell types (eg, macrophages, mast cells, lymphoid cells) may also be present. The extracellular matrix consists of ground substance and fibers. Ground substance consists largely of proteoglycans and hyaluronic acid, and there are 3 types of fiber secreted by connective tissue cells: collagen fibers, reticular fibers, and elastic fibers. The exact type of each connective tissue is determined by the ratio of cells to fibers within the extracellular matrix.<sup>3(pp91),4(pp159-160)</sup>

Connective tissue itself is divided into 2 types: connective tissue proper and specialized connective tissue (see Figure 1). Connective tissue proper can be further divided into loose and dense connective tissues (see Figure 2). The 3 types of loose connective tissue are: areolar, adipose, and reticular.<sup>5(pp36-42)</sup> Of particular interest to DOs is loose areolar connective tissue, which is what is commonly referred to when dealing with OMT techniques that involve treating fascial or myofascial somatic dysfunctions.<sup>6(pp78-80)</sup>

Dense connective tissue also has 3 types: regular, irregular, and elastic. Dense regular connective tissue is the basis for the formation of tendons, ligaments, and aponeuroses. Dense irregular connective tissue is found in tissues such as the dermis, fibrous capsules, periosteum, and perichondrium. Examples of dense elastic connective tissue include that which is found in the bronchial tubes and the *ligamentum flavum*.<sup>4(p161),5(p41)</sup>

Specialized connective tissue also can be divided into 3 types: blood and lymphoid tissue, bone, and cartilage (see Figure 3). The specific forms of cartilage are hyaline, elastic, and fibrocartilage. Hyaline cartilage is found as costal cartilage, as well as in such areas as the

Figure 1. Mesenchyme is the stem tissue of all the connective tissues of the body.

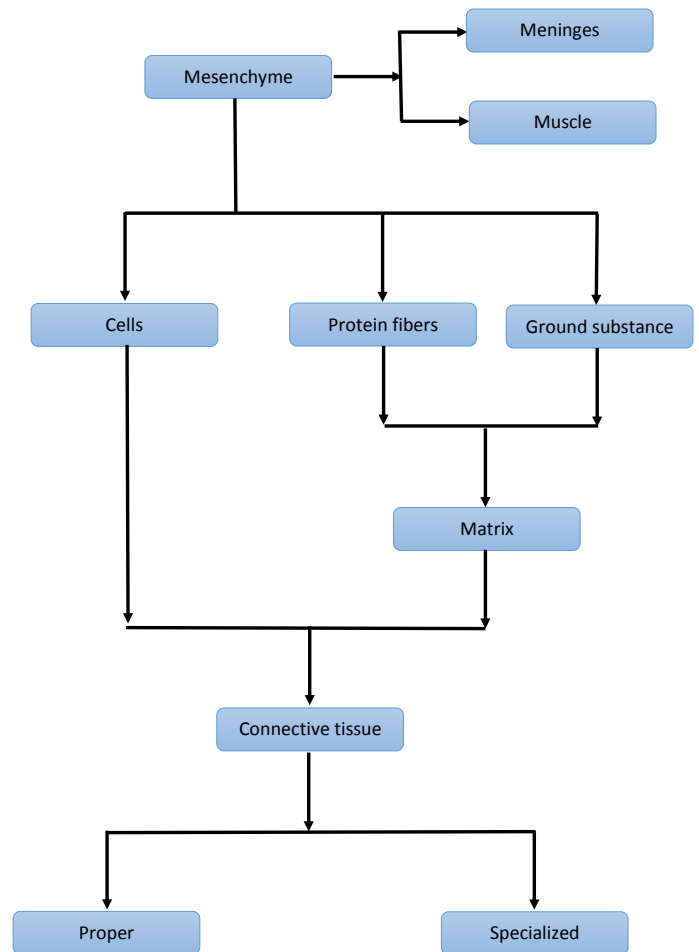
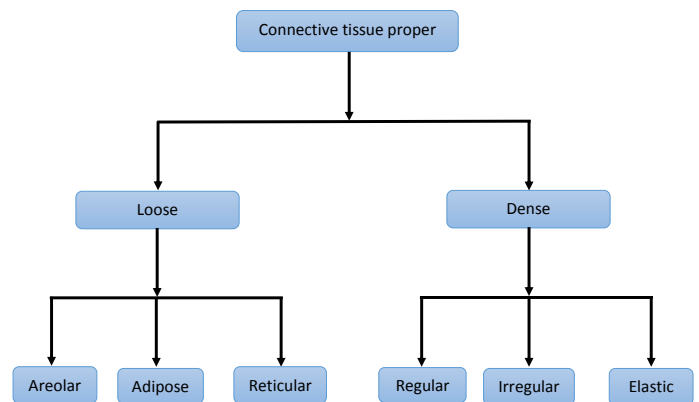


Figure 2. Connective tissue proper can be divided into loose and dense connective tissues.

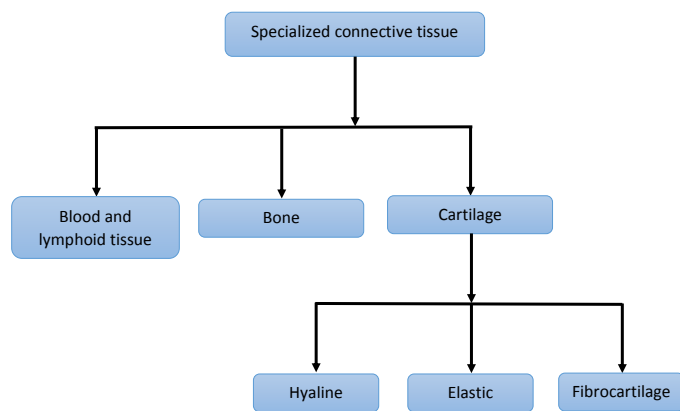


nose and larynx. Elastic cartilage helps to form such structures as the external ear and epiglottis. Fibrocartilage is particularly notable in structures such as the intervertebral disk or an articular labrum.<sup>3(pp129-133),4(pp199-205),5(pp84-86)</sup>

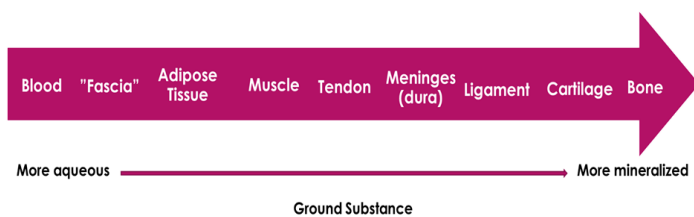
(continued on page 9)



**Figure 3.** Specialized connective tissue can be divided into 3 types: blood and lymphoid tissue, bone, and cartilage.



**Figure 4.** Connective tissue elements may be viewed as a “continuum” of tissues and structures.



*(continued from page 8)*

These classifications of connective tissue give rise to some notable points:

- The musculoskeletal elements of somatic dysfunction include tissues and structures such as bone, joint capsule, cartilage, ligament, tendon, muscle, and fascia.
- Any or all of them may be involved in the expression of somatic dysfunction in a given area.
- They may be seen as various forms of connective tissue.
- The properties of each of these elements depend upon the relative amounts of cells and fibers within the element’s extracellular matrix.

In fact, these connective tissue elements may be viewed as a continuum of tissues and structures, ranging from more fluid forms such as blood and plasma, to firm, hard structures such as bone, at the other end of the spectrum (see Figure 4). Alterations in the functions of these elements occur when they are involved in somatic dysfunction. Skilled DOs can palpate these alterations, thus determining which specific musculoskeletal elements need to be treated. Based on this information, DOs can select the most appropriate OMT modalities for the particular type of somatic dysfunction present. For example, restricted motion and imbalance in ligamentous structures may respond better to a functional or balanced ligamentous technique, whereas somatic dysfunction manifested

## Sutherland Cranial Teaching Foundation Upcoming Courses



### SCTF Basic Course: Osteopathy in the Cranial Field

June 9–13, 2016

Marian University College of Osteopathic Medicine  
3200 Cold Spring Road • Indianapolis, IN  
Course Director: Daniel Moore, D.O.  
40 hrs 1A CME anticipated • course cost: \$1,650

### SCTF Continuing Studies Course: The Eye

October 7–9, 2016

UNE-COM Alford Center for Health Sciences  
Biddeford, ME

Course Director: Michael Burruano, D.O., F.A.C.  
Schedule & course cost: TBA  
(visit the web site for updates)

Visit our website for enrollment forms  
and course details: [www.sctf.com](http://www.sctf.com)

Contact: Joy Cunningham 907-868-3372

Email: [jcunningham4715@yahoo.com](mailto:jcunningham4715@yahoo.com)

by hypertonic muscles would be better resolved using an isometric (muscle energy) approach.

### Diagnosing Somatic Dysfunction Using This Approach

In addition to using the patient’s medical history and physical examination, DOs perform an osteopathic structural examination (OSE) in the diagnostic process. The OSE is used to determine the presence of somatic dysfunction related to the patient’s presenting complaint(s). The examination<sup>7(pp22-40)</sup> is performed in 3 stages:

- the screening examination;
- the regional (scanning) examination;
- segmental definition (diagnosis) of somatic dysfunction.

#### The Screening Examination

In this portion of the OSE, the DO first takes in a general view of the whole patient, observing such things as posture, appearance, nutritional status, gait, and any evidence of gross asymmetries. The physician performs static and dynamic maneuvers. Abnormal findings indicate regions of the musculoskeletal system that require further evaluation for TART changes and segmental motion restrictions.

*(continued on page 10)*

*(continued from page 9)*

### **The Regional (Scanning) Examination**

This part of the OSE is performed to answer 2 questions:

- What area within the body region shows signs or symptoms of somatic dysfunction?
- What tissues within this region are affected?

The scanning examination is performed using a combination of static and dynamic testing procedures. Static testing is done by palpating the soft tissues (skin, subcutaneous tissues, muscles, ligaments, fascia) of the region in question, looking for tissue texture abnormalities such as hypertonicity, ropiness, bogginess, increased or decreased temperature, and increased or decreased moisture (see also TART above). The tissues within the region also may be palpated for discrete trigger points or tender points. Asymmetry of tissues or joint structures within a region may be observed as well as palpated.

Motion testing for the scanning examination takes the form of active and passive range of motion testing within the body region in question. Passive motion testing also will reveal any abnormalities in the quality of motion within the region. The examiner should note whether the motion being tested is smooth and equal in all possible directions or whether there is a feeling of excessive

tension in the tissues even though the quantitative range of motion may be normal. These static and dynamic tests allow the examiner to identify specific areas within body regions that may exhibit the presence of somatic dysfunction. Once these areas are identified, the examiner proceeds to segmental definition. In this part of the structural examination, individual vertebral segments or peripheral joints are identified and given a specific somatic dysfunction diagnosis. In addition, the examiner identifies the specific motion restrictions that are present and the tissues that are most involved in the dysfunctional segment.

### **Segmental Definition**

The final part of the structural evaluation is the segmental examination. This part of the structural evaluation determines the specific somatic dysfunctions that are present. It is designed to answer the following questions:

- What specific segments are dysfunctional? In this context, a segment may be defined as a vertebra, a rib, the sacrum or one of the innominate bones, or a specific upper or lower extremity joint.
- What are the specific motion restrictions present?
- What other tissues (such as muscle, ligaments, fascia) are involved?

*(continued on page 11)*



## **Full and Part-Time Faculty Positions Available: Department of Osteopathic Principles, Practices and Integration**

The University of the Incarnate Word School of Osteopathic Medicine (UIWSOM) educates aspiring physicians to be justice-minded, global citizens using a community-based, distributed model of education, which fosters inclusion, discovery and innovation.

**Responsibilities:** Participation in the design and implementation of a transformative, clinically relevant, integrated, competency-based osteopathic manipulative medicine and clinical skills curriculum.

**Qualifications:** D.O. degree from an accredited U.S. osteopathic medical school with unrestricted license to practice medicine in the state of Texas.

**Preferred Qualifications:** Board certification or board eligible in Neuromusculoskeletal Medicine/ Osteopathic Manipulative Medicine and/or board certification or board eligible in a field of primary care.

**For more information and to apply, please visit: <https://jobs.uiw.edu/>**

(continued from page 10)

- Are the somatic dysfunctions related to the patient's presenting problems?

The diagnosis of somatic dysfunction depends on determining motion loss at a given segment and the associated tissue characteristics that accompany this motion loss. Having determined during the regional examination an area within a body region that may exhibit somatic dysfunction, the examiner's goal now is to determine the specific segment that is dysfunctional, the specific motions that are restricted, and the associated tissues that may be causing or contributing to the motion restriction. If there are several segments involved within a particular body region, the examiner attempts to find the most restricted segment, that is, the segment that exhibits the greatest amount of motion restriction and associated tissue texture changes.

### The Barrier Concept

Identifying somatic dysfunction during the osteopathic structural examination requires the examiner to use any TART changes to identify clinically significant motion restriction in joints and tissues. In the structural examination of joints and tissues, DOs can identify both normal and abnormal barriers to joint and tissue motion. In any given motion plane, the total amount of motion from one extreme to the other is limited by what is called the *anatomical barrier*. This barrier is also the limit of passive range of motion of the joint or tissues in question. Moving the affected joint or tissues beyond the anatomical barrier may result in injury such as fracture, dislocation, or interruption of ligamentous structures.

Within this total range of motion defined by the anatomical barrier, there are several other normal motion barriers that are

significant.<sup>7(pp42-46)</sup> They are described as:

- The *physiologic barrier*: the limit of active range of motion of the joint or tissues.
- The *elastic barrier*: the range of motion between the physiologic and anatomic barrier, where passive ligamentous stretching takes place. The space between the physiologic and anatomic barriers has been described as the *paraphysiologic space*.

These normal motion barriers are illustrated in *Figure 5*.

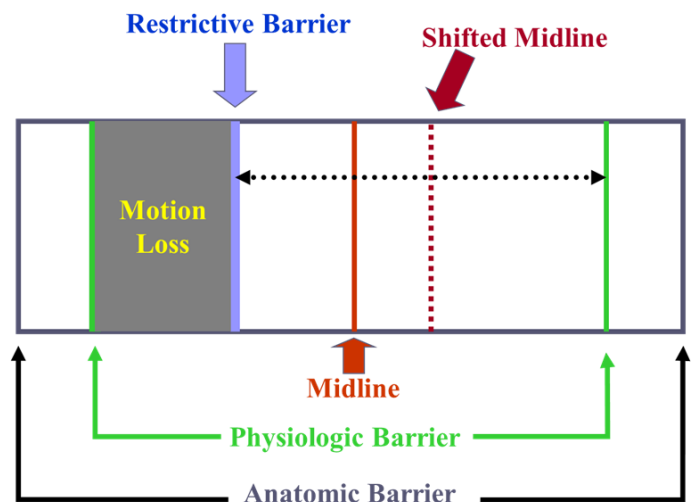
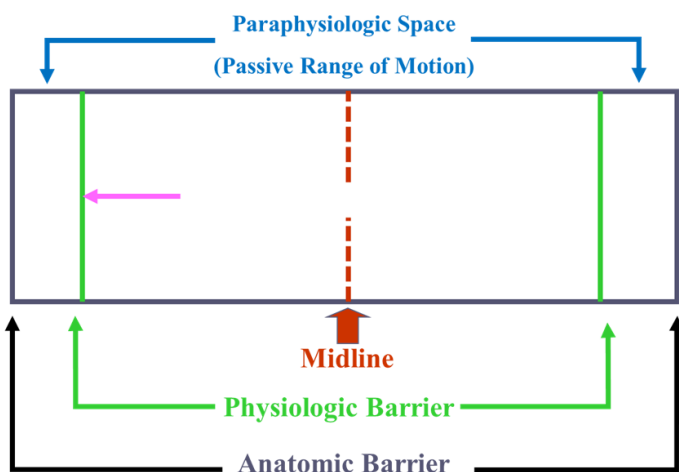
The following are abnormal motion barriers:

- The *restrictive barrier*: an obstruction to motion within the anatomical range that results in an abnormal limitation to the physiologic range.
- The *pathological barrier*: a permanent obstruction of joint motion due to pathology within the tissues, such as contractures or osteophytes.

With a normal joint or tissue, there is a midline point from which there is equal motion in either direction. When somatic dysfunction is present, some motion is lost, producing a *restrictive barrier* (see *Figure 6*). This restrictive barrier reduces or prevents motion in the direction of the motion loss. Thus the amount of active motion present is limited in one direction by the normal physiologic barrier and in the other direction by the restrictive barrier. The midline point shifts from its normal position to the middle of the active range of motion now available. The osteopathic physician uses the palpatory characteristics of the restrictive barrier to identify the

(continued on page 14)

**Figure 5.** An illustration of normal motion barriers.



**Figure 6.** When somatic dysfunction is present, some motion is lost, producing a restrictive barrier.

# TOURO UNIVERSITY CALIFORNIA

## Assistant/Associate Professor



TOURO UNIVERSITY  
CALIFORNIA

Touro University California, a rapidly growing university offering graduate programs in health sciences and education, has an excellent opportunity for an Assistant/Associate Professor for Touro University College of Osteopathic Medicine/Osteopathic Manipulative Medicine Department on our Mare Island campus. The university is part of the Touro College and University System and is located on the northern tip of San Francisco Bay in Vallejo, California. Touro University California is an independent, non-profit Jewish-sponsored institution. It has 1,403 students in three graduate professional colleges (Osteopathic Medicine, Pharmacy, Education and Health Sciences).

**POSITION DESCRIPTION:** is not intended to cover every work assignment a position may have. Rather, they cover the broad responsibilities of the position.

Typical department duties will be designed to fulfill OMM department goals and priorities in delivering OMM curriculum in the preclinical and clinical periods of TUCOM curriculum. Personal and professional development faculty development will be considered in the assigning of duties in the effort to create a rewarding collegial work environment Duties will include but not be limited to the following<sup>1</sup>:

- Generation and delivery of OMM didactic lectures, preclinical and clinical lab experiences <sup>1</sup>
- Weekly participation OMM Laboratories (or Practical exams)
- Weekly approved clinical service <sup>2</sup>
- Weekly attendance to OMM Department Meetings
- Weekly administrative Time <sup>3</sup>
- University Service as assigned by Department Chair <sup>4</sup>
- Other Assignments as required by the Department Chair <sup>5</sup>

**REPORTS TO:** Chair of OMM Department

**SPECIFIC RESPONSIBILITIES:** are those work assignments which are predominant, regular and recurring.

These categories and times may be modified in consultation with the department chair to better meet the needs of the department and the faculty member. It is the responsibility of each faculty member to keep the department chair informed of work activities and projects. This should be done by consultation with the chair and/or submission of monthly activity reports within two weeks of the end of the month. Each faculty member is also responsible for submitting a monthly leave report within two weeks of the end of the month. It is expected that every faculty member will behave and interact with students, staff and faculty in a collegial and professional manner.

• All efforts will be made to distribute among the department the lecture/lab teaching load in an equitable manner, although the exact numbers of each may vary. First year faculty with limited academic experience are expected to attend departmental lectures as determined by the departmental chair. Variation from this standard may be given at the discretion of the department chair to meet departmental needs.

**QUALIFICATIONS:** is the Education, Training and/or related experience needed by the person to perform the job.

Applicant should be committed to the support and development of the next generation of enthusiastic Osteopathic physicians. This would include (but not necessarily limited to) modeling applied Osteopathic philosophies, OMM clinical integration, sound clinical decision processes, and moral/ethical sensitivity into clinical practice through the use of competent palpatory diagnosis and treatment.

° Active board certification in OMM/NMM or board eligible or

- ° Active other applicable specialty board certification with demonstrable OMM skills
- ° Clinical practice experience
- ° Licensed or ability to be licensed in the State of California - **Required**
- ° Unrestricted DEA licensure - **Required**
- ° Graduate of an AOA-approved osteopathic college - **Required**
- ° Residency training and teaching experience desirable
- ° Research experience or interest desirable

### **RANK, SALARY, AND BENEFITS:**

- Assistant or Associate Professor as determined by Touro Rank and Promotion Committee
- Salary based on experience and credentials
- Touro University faculty benefit package
- Clinic stipend and bonuses available
- Relocation assistance available

Informal interest/inquiries may be directed to:

R. Mitchell Hiserote, DO  
Associate Professor and Chairman  
Department of Osteopathic Manipulative Medicine  
Touro University-California  
(707) 638-5945, Fax (707) 638-5946,  
email: mitchell.hiserote@tu.edu

Salary is competitive and commensurate with background and experience.

If you are interested in learning more about faculty opportunities at Touro University California, College of Osteopathic Medicine, please e-mail your CV and a letter of interest to:

Search Committee  
Email: [Apply@tu.edu](mailto:Apply@tu.edu)  
Subject: Your Name, Assistant/Associate Professor OMM  
or Mail: Touro University California  
1310 Club Drive Vallejo, CA 94592

For more information please visit our website <http://apptrkr.com/694378>

Touro University California is an Equal Opportunity/Affirmative Action Employer

Touro is a system of Jewish-sponsored non-profit institutions of higher and professional education. Touro College was chartered in 1970 primarily to enrich the Jewish heritage, and to serve the larger American community. Approximately 19,000 students are currently enrolled in its various schools and divisions. Touro College has branch campuses, locations and instructional sites in the New York area, as well as branch campuses and programs in Berlin, Jerusalem, Moscow, Paris, and Florida. Touro University California and its Nevada branch campus, as well as Touro College Los Angeles, are separately accredited institutions within the Touro College and University System. For further information on Touro College, please go to: <http://www.touro.edu/media/>

# INTRODUCTION TO OSTEOPATHIC MANIPULATIVE MEDICINE

June 16-19, 2016 • University of North Texas Health Science Center  
Texas College of Osteopathic Medicine in Fort Worth

This is the first in a series of courses that the American Academy of Osteopathy (AAO) will be conducting to help MD students and graduates obtain the prerequisites for entering osteopathic-recognized residencies accredited by the Accreditation Council for Graduate Medical Education (ACGME). This course will also be valuable for DO and MD faculty in these residency programs.

In addition, osteopathic physicians who do not use osteopathic manipulative treatment (OMT) daily will find this course useful, as will other health care professionals with limited or no experience with manipulative techniques.

Through a combination of lectures and hands-on workshops, attendees will learn the basics of osteopathic manipulative medicine, which encompasses osteopathic tenets, palpatory diagnosis and OMT.

The curriculum includes lessons on muscle energy technique; thoracic spine technique; articular techniques; functional techniques; myofascial release; and high-velocity, low-amplitude thrust.

This course, which is supported in part by the AAO's Samuel V. Robuck Fund, will provide content applicable to both adult and pediatric patients.

## Course Times

Thursday from noon to 6 p.m.

Friday, Saturday and Sunday from 8 a.m. to 5:30 p.m.

## Continuing Medical Education

28 credits of NMM- and FP-specific AOA Category 1-A CME anticipated.

## Meal Information

Lunch will be provided Thursday through Saturday. Breakfast will be provided Friday through Sunday. Please contact the Academy with special dietary needs at (317) 879-1881, ext. 220, or [EventPlanner@academyofosteopathy.org](mailto:EventPlanner@academyofosteopathy.org).

## Course Location

University of North Texas Health Science Center  
Texas College of Osteopathic Medicine  
3500 Camp Bowie Blvd., Fort Worth, TX 76107



## Course Director

**Lisa Ann DeStefano, DO**, has chaired the Department of Osteopathic Manipulative Medicine at the Michigan State University College of Osteopathic Medicine (MSUCOM) in East Lansing since 2004. A protégé of the late Philip E. Greenman, DO, FAAODist, Dr. DeStefano edited the fourth edition of the

textbook *Greenman's Principles of Manual Medicine*.

A 1993 graduate of MSUCOM, Dr. DeStefano is board certified in osteopathic manipulative medicine and neuromusculoskeletal medicine and in osteopathic family medicine. In 2003, she received the Osteopathic Faculty Award and the Guiding Principles Award from MSUCOM. She has lectured widely in the United States and internationally.

## Travel Arrangements

Contact Tina Callahan of Globally Yours Travel at (800) 274-5975 or [globallyyourstravel@cox.net](mailto:globallyyourstravel@cox.net).

Registration Fees	Until April 16, 2016	April 17 through May 17, 2016	After May 17, 2016
Academy member in practice*	\$784	\$834	\$984
Resident or intern member	\$584	\$634	\$784
Student member	\$384	\$434	\$584
Nonmember practicing DO or other health care professional	\$984	\$1,034	\$1,184
Nonmember resident or intern	\$784	\$834	\$984
Nonmember student	\$584	\$634	\$784

\* The AAO's associate members, international affiliates and supporter members are entitled to register at the same fees as full members.

## Registration Form

### Introduction to Osteopathic Manipulative Medicine

June 16-19, 2016

Name: \_\_\_\_\_ AOA No.: \_\_\_\_\_

Nickname for badge: \_\_\_\_\_

Street address: \_\_\_\_\_

City: \_\_\_\_\_ State: \_\_\_\_\_ ZIP: \_\_\_\_\_

Phone: \_\_\_\_\_ Fax: \_\_\_\_\_

Email: \_\_\_\_\_

- I am a practicing health care professional.
- I am a resident or intern.
- I am an osteopathic or allopathic medical student.

The AAO accepts check, Visa, MasterCard and Discover payments in U.S. dollars. The AAO does not accept American Express.

Credit card No.: \_\_\_\_\_

Cardholder's name: \_\_\_\_\_

Expiration date: \_\_\_\_\_ 3-digit CVV No.: \_\_\_\_\_

Billing address (if different): \_\_\_\_\_

I hereby authorize the American Academy of Osteopathy to charge the above credit card for the amount of the course registration.

Signature: \_\_\_\_\_

Click here to view the [AAO's cancellation and refund policy](#).

Click here to view the [AAO's photo release statement](#).



Register online at [www.academyofosteopathy.org](http://www.academyofosteopathy.org), or submit this registration form and your payment by email to [EventPlanner@academyofosteopathy.org](mailto:EventPlanner@academyofosteopathy.org); by mail to the American Academy of Osteopathy, 3500 DePauw Blvd., Suite 1100, Indianapolis, IN 46268-1136; or by fax at (317) 879-0563.



*(continued from page 11)*

type of somatic dysfunction present, that is, the tissues or structures most responsible for the motion restriction that is present.

Somatic dysfunction can be categorized by the tissue or structure most responsible for the motion restriction at that segment.<sup>6(p434-435)</sup>

The following are types of somatic dysfunction:

- Arthrodiastolic restriction, resulting from restrictions between joint surfaces themselves.
- Muscular restriction, generally due to hypertonicity of muscles, but may also be associated with other pathological processes, such as contracture. Such changes may alter the positional and motion characteristics of the involved joint structures.
- Fascial and ligamentous restriction: These tissues can become shortened due to fibrosis resulting from trauma, inflammation, congenital or developmental conditions, disuse, or injury. A further distinction should be mentioned here: Motion restriction due to abnormal ligamentous tension is sometimes also referred to as *ligamentous articular strain*; within the primary respiratory mechanism (PRM), analogous motion restrictions may occur secondarily to abnormal tension in the meninges, particularly the *dura mater*. This type of restricted motion within the PRM is referred to as *membranous articular strain*.<sup>8</sup>
- Edematous restriction: Abnormal fluid accumulation within body tissues can result in motion restriction. This is thought to be due to pain resulting from the distention and stretching of fascial tissues, as a result of the presence of the fluid itself.

## End-feel

The most important characteristic of the restrictive barrier for determining the type of somatic dysfunction present (and subsequently the most appropriate type of OMT for treating the somatic dysfunction) is end-feel. End-feel is the quality of the resistance to movement that the examiner feels when coming to the end point of a particular movement.<sup>9</sup> This sensation is typically felt by the clinician when overpressure (additional movement applied after resistance to motion is felt) is applied at the end of passive range of motion.

End-feel can be further described as physiologic or pathophysiologic. Physiologic end-feel occurs as a result of limitations of passive range of motion by normally functioning structures such as bone, capsular tissues, or ligaments. Pathophysiologic end-feel occurs when there are pathological limits to motion, such as capsule or ligament contracture before full range of motion is reached, muscle spasm, loose bodies, or the patient's unwillingness to allow the completion of the motion.

In respect to osteopathic structural diagnosis and treatment, other authors have provided additional information on the use of end-feel. For example, Ehrenfeuchter<sup>6(p435)</sup> writes:

The concept of end-feel is one in which the characteristics of how the tissue feels at the end of range of motion testing for large joint motions, or for segmental motion testing, has significant implications for the osteopathic physician. The quality of the end-feel is used to determine the most likely etiology of the motion restriction (articular, muscular, fascial, edema). Once this is determined, it is used by the physician to guide in the selection of which osteopathic manipulative technique would be most useful in addressing that particular region or dysfunction.

Ehrenfeuchter further describes the end-feel characteristics of each of the above types of somatic dysfunction as follows: Edema exhibits a mushy or fluid-filled sponge kind of end-feel; muscle hypertonicity has a somewhat stretchy or rubbery end-feel; the end-feel in arthrodiastolic dysfunctions is more solid, with an accompanying loss of the elasticity usually felt in muscular or edematous restrictions; chronic ligamentous and fascial restrictions exhibit a very hard, abrupt end-feel with near total loss of tissue elasticity.<sup>6(p436)</sup>

Bourdillon<sup>10</sup> has similar observations, stating that there are different types of end-feels that occur at or near the restrictive barrier and reflect different causative factors for the associated restriction. Bourdillon describes the following end-feels:

- boggy, associated with edematous states;
- elastic or spring-like, associated with myofascial shortening;
- an asymmetrical and reduced range of motion associated with an early, gradual increasing resistance with a residual spring-like sensation at the end of the remaining free range of motion, associated with hypertonic musculature;
- a very rapid build-up in tension occurring close to the limiting barrier, but some elasticity that is slightly more firm than that felt from hypertonic muscle, associated with fibrosis (chronic myofascial shortening);
- a hard, nonelastic end-feel with an abrupt stop short of the normal range, associated with bony changes, such as hypertrophy of bone at articulations or altered bony anatomy due to disease or developmental conditions;
- an empty end-feel, which occurs when the patient expresses severe pain, but no resistance is palpable to the examiner; and
- hypermobility, manifested by very little resistance until close to the anatomical or bony barrier, when the tension builds

*(continued on page 15)*

*(continued from page 14)*

rapidly to a sense of hardness and there is a detectable, overall increase in range.

Greenman<sup>7(p46)</sup> notes that restrictive barriers can originate within any of the following tissues or structures: skin, fascia, muscle, ligament, or joint capsule and surfaces. He also describes the following end-feels:

- boggy, associated with edematous states;
- rapidly ascending end-feel that is harder and more unyielding than that associated with edema, and typically present in fibrotic states (chronic myofascial shortening);
- a more “jerky” and tightening type of end-feel than that associated with edema, associated with altered muscle physiology (hypertonicity, spasm, contracture);
- an empty feel, associated with marked pain; and
- hypermobility, associated with a sense of looseness for a greater amount of the range of motion than one would anticipate, followed by a rapidly increasing hard end-feel when approaching the elastic and anatomic barriers.

### Choosing Appropriate OMT modalities

The approach proposed in this paper suggests that an accurate diagnosis of somatic dysfunction and rational selection of appropriate

OMT modalities, can be achieved by the osteopathic physician’s use of:

- knowledge of anatomy, physiology, and biomechanics;
- the connective tissue origins of the tissues involved in the diagnosed somatic dysfunctions;
- the history and physical examination;
- the osteopathic structural examination; and
- the end-feel characteristics of the tissues involved in the somatic dysfunctions diagnosed.

*Table 1* summarizes this information and shows examples of possible OMT modalities that can be used to treat the types of somatic dysfunction discussed in this paper. The reader should note that while a variety of OMT modalities have been developed, the Educational Council on Osteopathic Principles (ECOP)<sup>11</sup> of the American Association of College of Osteopathic Medicine has designated 7 of these modalities as being most commonly used by clinicians and consistently taught by all colleges of osteopathic medicine in the United States. These 7 modalities are:

- counterstrain;
- high-velocity, low-amplitude (HVLA) thrust;
- muscle energy technique (MET);

*(continued on page 16)*

**Table.** Summary of somatic dysfunction characteristics and suggested choice of OMT modality.

Somatic dysfunction type	Tissue(s) involved	Connective tissue origin	Associated end-feel type	End-feel type description	Examples of possible OMT modalities
Arthrodial	Joint surfaces	Specialized connective tissue (bone)	Abrupt, solid, loss of elasticity	Abrupt end-feel, earlier than the expected range of motion (ROM), no “give” or elasticity, often painful	High-velocity, low-amplitude (HVLA); articular technique
Muscular	Muscles	Mesenchyme (various mesodermal layers)	Stretchy or rubbery	Asymmetric ROM, gradually increasing resistance, spring-like resistance at end of free motion	Soft tissue technique; muscle energy technique (MET)
Fascial	Fascial	Loose areolar connective tissue	Elastic, springy	Acute: shortened ROM but still elastic or spring-like Chronic: rapid tension build-up, slight elasticity but generally a more abrupt end-feel	Myofascial release (MFR) technique
Ligamentous	Ligaments, tendons, joint capsule	Dense regular connective tissue	Shortened ROM with gradual resistance and some remaining elasticity	Acute: similar to acute fascial restrictions, but less elasticity and springiness Chronic: harder, more abrupt, with only slight elasticity or springiness	Balanced ligamentous tension (BLT)
Edematous	Abnormal fluid accumulation within body tissues	Motion of various tissues is affected by abnormal and excessive fluid accumulation	Boggy	Mushy, sponge-like	Lymphatic techniques

(continued from page 15)

- myofascial release (MFR);
- lymphatic technique;
- osteopathic cranial manipulative medicine (OCMM); and
- soft tissue.

Closely related to OCMM are *balanced ligamentous tension* and *balanced membranous tension*.

While other proposed modalities can easily be applied to this approach, the examples of OMT modalities listed in *Table 1* are from the ECOP list of 7 major modalities.

Clinically, it is possible for 1 or more tissue types to be involved in a given somatic dysfunction, and thus, it is possible for 1 or more kinds of end-feel to be exhibited. Each restrictive barrier will respond to the appropriate OMT modality, based on its end-feel characteristics. Each additional restrictive barrier is evaluated and treated with appropriate OMT until the osteopathic physician determines that physiologic motion in this restricted region or segment has been maximized. For example, an edematous restriction may be relieved through the use of lymphatic or myofascial release techniques, only to reveal an arthroal somatic dysfunction that requires treatment with an OMT modality directed to the joint surfaces themselves, such as articulatory technique or a high-velocity, low-amplitude thrust approach.

One must remember that there also can be situations such as in the case of an inexperienced clinician, where the restrictive barrier in a given somatic dysfunction is not properly located and the end-feel

### CONTINUING MEDICAL EDUCATION QUIZ

The purpose of the continuing medical education quiz—found on page 25—is to provide a convenient means of self-assessing your comprehension of the scientific content in the article “The Use of Osteopathic Manipulative Treatment for Acute Dental Pain: A Case Report” by Karen Teten Snider, DO, FAAO.

Be sure to answer each question in the quiz. The correct answers will be published in the next issue of the *AAOJ*.

To apply for 2 credits of AOA Category 2-B continuing medical education, fill out the form on page 25 and submit it to the American Academy of Osteopathy. The AAO will note that you submitted the form and forward your results to the American Osteopathic Association’s Division of Continuing Medical Education for documentation.

You must score a 75% or higher on the quiz to receive CME credit.

associated with it incorrectly interpreted. In such a case, failure to accurately engage the restrictive barrier or apply the most appropriate OMT modality may result in less than optimum treatment results or even failure of the technique to work.

### Summary

An osteopathic structural examination to diagnose clinically relevant somatic dysfunction is an essential part of the complete evaluation of the patient. Using their knowledge of anatomy, physiology and biomechanics, osteopathic physicians locate restrictive barriers to physiologic motion and then determines which tissues or structures are responsible for these barriers. This is accomplished by noting the total range of motion present, the quality of the motion, and the end-feel at the barrier. With this knowledge, the osteopathic physician can choose, from multiple OMT modalities and activating forces available, the most appropriate manipulative approaches for the goal of achieving maximum physiologic motion.

### References

1. Van Buskirk RL. *The Still Technique Manual: Applications of a Rediscovered Technique of Andrew Taylor Still, M.D.*, 2nd ed. Indianapolis, IN: American Academy of Osteopathy; 2006:9-10.
2. Educational Council on Osteopathic Principles. *Glossary of Osteopathic Terminology*. Chevy Chase, MD: American Association of Colleges of Osteopathic Medicine; 2011:53.
3. Junqueira LC, Carneiro J. *Basic Histology: Text and Atlas*. 11th ed. New York, NY: The McGraw-Hill Companies, Inc.; 2011.
4. Ross MH, Pawlina W. *Histology: A Text and Atlas*. 6th ed. Baltimore: Lippincott Williams & Wilkins; 2011.
5. Sandring S, ed. *Gray’s Anatomy: The Anatomical Basis of Clinical Practice*. 39th ed. Edinburgh, Scotland: Churchill Livingstone; 2005.
6. Chila AG, ed. *Foundations of Osteopathic Medicine*. 3rd ed. Philadelphia, PA: Lippincott Williams & Wilkins; 2011.
7. DeStefano LA. *Greenman’s Principles of Manual Medicine*. 4th ed. Philadelphia, PA: Lippincott Williams & Wilkins; 2011: 22-40.
8. Hrubby RJ. Balanced Ligamentous Tension techniques. In: Chaitow L. *Positional Release Techniques*. 4th ed. Edinburgh, Scotland: Elsevier; 2015:180.
9. Magee DJ. *Orthopedic Physical Assessment*. St. Louis, MO: Saunders Elsevier; 2008:21.
10. Issacs ER, Bookhout MR. *Bourdillon’s Spinal Manipulation*. 6th ed. Boston, MA: Butterworth-Heinemann; 2002:39.
11. Hensel K, ed. *A Teaching Guide for Osteopathic Manipulative Medicine*. Chevy Chase, MD: American Association of Colleges of Osteopathic Medicine; 2015:1. ■

Follow the AAO online:





# The Use of Osteopathic Manipulative Treatment for Acute Dental Pain: A Case Report

Karen Teten Snider, DO, FAAO

CASE REPORT

## Abstract

Acute dental pain may result from a localized process, such as an abscess, or it may be the result of pain referral from the musculoskeletal structures of the orofacial, head, and neck regions. The following case report demonstrates the use of osteopathic manipulation treatment (OMT) in the management of acute undifferentiated dental pain in the absence of overt signs of infection.

In this case, a 55-year-old female with a history of temporomandibular joint dysfunction and thoracic outlet syndrome presented to an outpatient neuromusculoskeletal medicine clinic with a 1-day history of dental pain. Physical examination revealed marked pressure sensitivity of the right upper first molar and right-side cervical lymphadenopathy, but no swelling in the surrounding soft tissues. Articular and myofascial somatic dysfunctions were found in the head, cervical, thoracic, and rib regions. OMT, including cranial, articular, myofascial release, and Still techniques, was used to treat the somatic dysfunctions found. These techniques, which also included an intraoral myofascial release of the sensitive tooth, afforded the patient immediate improvement in pain and pressure sensitivity and complete resolution of the symptoms within 24 hours.

This case report discusses how preexisting biomechanical dysfunction may have predisposed the patient to her acute symptoms, and it explores potential mechanisms of the successful OMT, including optimization of vascular and lymphatic drainage, normalization of autonomic tone, and improvement of regional biomechanics.

## History

A 55-year-old female presented to the osteopathic manipulative medicine (OMM) clinic at the A.T. Still University–Kirksville College of Osteopathic Medicine in Missouri with a 1-day history of right dental pain. Having been treated 10 weeks previously for thoracic outlet syndrome, the patient had returned for a follow-up visit. She had been doing her prescribed stretches for her thoracic outlet syndrome and denied numbness or tingling in her upper extremities.

The patient reported that the jaw pain was preceded by a lump appearing in her right upper cervical area the day before pain began. The next morning the lump was gone, but the patient

From the A.T. Still University–Kirksville College of Osteopathic Medicine in Missouri

Financial disclosure: none reported.

Correspondence address:

Karen Teten Snider, DO, FAAO  
Department of Family Medicine,  
Preventive Medicine and Community Health  
A.T. Still University–  
Kirksville College of Osteopathic Medicine  
800 W. Jefferson St.  
Kirksville, MO 63501-1443  
(660) 626-2304  
[KSnyder@atsu.edu](mailto:KSnyder@atsu.edu)

Submitted for publication May 7, 2015; final revision received February 18, 2016; manuscript accepted March 3, 2016.

experienced pain in the right upper jaw localized to the upper first molar. She was unable to chew on the right side once the pain began, but she denied temperature sensitivity. The patient had a history of temporal mandibular joint dysfunction (TMD), and she reported that pain was typically localized in the right temporal mandibular joint (TMJ) and occurred with mouth opening. The current pain was more consistent with that of a previous dental abscess. She denied previous orofacial pain in the current location. She had not received osteopathic manipulative treatment (OMT) since she was treated 10 weeks previously for thoracic outlet syndrome.

The patient has a history of obesity, type 2 diabetes mellitus, hyperlipidemia, hypertension, lower extremity varicose veins, cervicogenic vertigo and motion sickness, thoracic outlet syndrome, chronic postural dysfunction, TMD, and 1 dental abscess in the left lower jaw. She has had a total abdominal hysterectomy and oophorectomy, tonsillectomy, cesarean section, cholecystectomy, and a root canal oral surgery. The patient's mother, father, and

*(continued on page 18)*

*(continued from page 17)*

brother have type 2 diabetes mellitus, and her mother also has varicose veins. The patient is married and has 2 adult children in good health. She is an office-based social worker for a state agency. She is a nonsmoker, and she drinks less than 1 alcoholic beverage a month. She drinks 32 fl oz of caffeinated sugar-free beverage daily. She had been performing her scalene stretches for her thoracic outlet syndrome once a day, 3 to 4 days a week, as instructed at the previous visit. She takes 20 mg of lisinopril daily, 500 mg of metformin daily, 40 mg of simvastatin daily, and 4 mg of tizanidine every 8 hours as needed for muscle spasms. She has no known drug allergies.

In addition to her current symptoms, the patient also reported occasional back pain and neck pain. She is morbidly obese, and she reported a planned weight loss of 5 lbs since her previous visit. She denied recent fever, lethargy, pallor, cough, dyspnea, abdominal pain, constipation, diarrhea, chest pain, irregular heartbeat, palpitations, anxiety, depression, insomnia, headaches, rashes, or allergies. She had not had symptoms of her thoracic outlet syndrome, including numbness or tingling in the extremities, for the past 2 months. She denied recent muscle spasms or bruising.

### Physical Examination

On physical examination, the patient's blood pressure was 136/72, heart rate was 72, respiratory rate was 16, weight was 260 lbs, and her body mass index was 42. She was oriented to time, place, person, and situation, and she demonstrated appropriate mood, affect, insight, and judgment. No abnormalities of the nasal or oral mucosa were noted. No tenderness over the maxillary sinuses was noted. Mild staining of the dental surfaces was noted, but no obvious decay was evident. No abnormalities of the external auditory canals or tympanic membranes were noted. Marked pressure sensitivity was demonstrated at the right upper first molar when the patient bit on a wooden stick held between the upper and lower right first molars. No pressure sensitivity was noted for the other teeth. No gingival swelling or temperature sensitivity was noted. A single enlarged lymph node was palpated in the upper right anterior cervical chain.

The patient has an anterior head carriage consistent with her chronic postural dysfunction. A slight deviation of the mandible to the left was noted upon mouth opening. No pain or crepitus were appreciated. The right maxilla was internally rotated. The right zygoma was internally rotated. The right temporal bone was internally rotated. The hyoid was translated to the right with a tight right stylohyoid muscle. The occipitoatlantal (OA) joint

*(continued on page 19)*



Have you seen our books yet?

Have a look at a trial version of all our books on osteopathic medicine.

Visit our online store at [www.osteopathy.eu/en/webshop/studybooks](http://www.osteopathy.eu/en/webshop/studybooks).

*(continued from page 18)*

was extended, sidebent left, and rotated right. Right suboccipital muscular tension was present. C2 was flexed, sidebent right, and rotated right. Bilateral cervical paraspinal muscle tension was present. The right rib 1 was inhaled. Right thoracic inlet myofascial restrictions were present. Boggy congestion was noted in the right supraclavicular area. T1 was flexed, sidebent right, and rotated right. T4 through T6 were neutral, sidebent right, and rotated left.

No significant somatic dysfunctions were noted in the lumbar, pelvis, sacrum, or lower extremity regions.

The patient's assessment included jaw pain (ICD-9 784.92); cervical lymphadenopathy (ICD-9 785.6); somatic dysfunction of the head region (ICD-9 739.0), the cervical region (ICD-9 739.1), the thoracic region (ICD-9 739.2), and the rib cage (ICD-9 739.8).

### **Treatment**

Based on the physical examination, OMT was used to treat the somatic dysfunctions. The head area was treated using articular technique, osteopathic cranial manipulation, Still technique, and myofascial release, including an indirect myofascial release of the right upper first molar. The cervical area was treated using articular technique, Still technique, and myofascial release. The thoracic area was treated using articular technique, Still technique, and myofascial release. And the thoracic inlet and rib areas were treated using articular technique, Still technique, and myofascial release. Following treatment, somatic dysfunction was improved in all areas with a 75% reduction in symptoms and oral pressure sensitivity.

Before visiting the clinic, the patient had scheduled an appointment with her dentist for the next day. An antibiotic prescription was offered for a suspected dental abscess, but the patient opted to wait until she saw her dentist the next day.

The patient scheduled a follow-up appointment for 6 weeks later to review her thoracic outlet syndrome. She was encouraged to continue her home stretches and to increase her level of physical activity.

The patient returned for follow-up 6 weeks later. The cervical lymphadenopathy had resolved, and she reported that her orofacial pain had completely resolved by the day after her previous visit. Despite the resolution of the pain, she saw her dentist as planned. No abnormalities were found, and she had her teeth cleaned without pain or difficulty. She reported a single episode of upper extremity numbness and tingling since her previous visit, but she admitted that she had stopped doing her stretches. The tingling resolved after the patient resumed her stretching routine.

Six months after her initial presentation with acute orofacial pain, the patient opened her mouth wide to bite into a large sandwich and experienced sudden onset right jaw pain. A few days later, she saw her dentist for her regularly scheduled dental visit, and the dentist ordered a magnetic resonance image (MRI) of the right TMJ. The MRI revealed the disc had moderate degeneration with abnormal translation. She was then prescribed 35mg of diclofenac twice daily, and she started wearing a bite guard at night to prevent bruxism.

In the year following her initial OMM presentation with orofacial pain, the patient had no recurrence of localized pain at the right upper first molar. She had several exacerbations of jaw pain that responded well to OMT to the head, neck, cervical, and thoracic regions. She was taught exercises to strengthen the jaw muscles and cervical flexors. She continues to use her bite guard nightly, and she takes 35mg of diclofenac as needed for acute jaw pain.

### **Discussion**

The patient in the current case report was treated with the assumption that she was developing a dental abscess. Therefore, OMT was directed toward optimizing lymphatic drainage from the affected structure and toward normalizing autonomic nervous tone to maximize the body's ability to clear the infection. Simple dental abscesses are localized anaerobic bacterial infections that cause sensitivity to mastication with localized swelling adjacent to the apex of the infected tooth.<sup>1</sup> As the infection spreads into the surrounding fascial tissues, cellulitis develops and systemic symptoms such as fever appear.<sup>2</sup> Abscesses of the maxillary molar teeth typically spread into the buccal space between the buccinator muscle and the skin, creating facial swelling.<sup>2</sup>

Classically, simple dental abscesses have been treated with drainage and irrigation, saline oral rinses, and oral antibiotics such as penicillin or doxycycline.<sup>1</sup> More recently, antibiotic treatment in the absence of systemic infection has been called into question. Runyon et al<sup>3</sup> found that in the absence of signs of overt infection, the use of antibiotics had no statistically significant difference in outcomes in patients presenting to the emergency room with acute dental pain. In their study,<sup>3</sup> 9% of both penicillin- and placebo-treated groups went on to develop overt signs of infection within 5 to 7 days. Other studies suggest that in the presence of localized periapical swelling, drainage is typically sufficient to reduce the total bacterial load and to promote aerobic conditions to the point where the body's own systems can handle the infection.<sup>4</sup> Therefore, the routine use of antibiotics for dental pain from a simple abscess without systemic symptoms, such as fever or facial swelling, is no longer recommended.<sup>3,5</sup>

*(continued on page 20)*

## CLASSIFIED ADVERTISEMENTS

### AAO Yearbooks

Complete set of 37 volumes including the original 1937-38 mimeographed editions. These used copies are in good to excellent condition. \$2,000 or best reasonable offer. Contact David A. Patriquin, DO, FAAO, at (802) 258-3076.

### 3 NMM+1, 3 NMM/FP POSITIONS AVAILABLE IN SUNNY SOUTH FLORIDA

Larkin Hospital in Miami has 3 NMM+1 residencies that begin in July 2016, October 2016 and January 2017. In addition, there are 3 NMM/FP residency opportunities starting in July 2016. Contact Joel D. Stein, DO, FAAO, at (954) 563-2707 or [ommdoc@aol.com](mailto:ommdoc@aol.com) for more information.

### NMM PLUS 1 RESIDENCY PROGRAM IN NEW YORK

NMM Plus 1 Residency at Southampton Hospital in beautiful Southampton, Long Island. Applications are currently being accepted. If interested, please contact Program Director Denise K. Burns, DO, FAAO, at [drdenise@optonline.net](mailto:drdenise@optonline.net) or Education Department Secretary Karen Roberts at (631) 726-0409.

### *(continued from page 19)*

The patient in the current case had no overt signs of infection, only localized pain and pressure sensitivity consistent with a previous dental abscess and the acutely enlarged lymph node in the anterior cervical chain, which drains the maxillary region.<sup>6</sup> OMT was directed at improving vascular and lymphatic drainage from the right maxilla by treating the fascial diaphragms at the occipito-cervical region, hyoid, and thoracic inlet and by treating the fascial attachments of the painful tooth.<sup>7</sup>

To normalize parasympathetic tone, OMT was directed at somatic dysfunction that could affect the course of the facial and vagus nerves, such as the OA joint, C2, and the temporal and facial bones.<sup>7</sup> To normalize the sympathetic tone, OMT was directed at somatic dysfunction that could affect the sympathetic nerves to the head as they course from the upper thoracic spine through the cervical region and the pterygopalatine fossa.<sup>7</sup> The complete resolution of symptoms on the day following the OMT suggests that either the treatment successfully helped the patient's body fight the emerging infection or that the patient was suffering from a musculoskeletal issue related to her TMD.

TMD is a generic term used to describe a variety of TMJ dysfunctions, including myofascial pain syndrome, internal disc derangement, and osteoarthritis.<sup>8</sup> Dysfunction in the TMJ may refer pain to the surrounding muscles such as the masseter via shared trigeminal nerve innervation.<sup>9,10</sup> Alternatively, altered biomechanics may result in abnormal muscular activity through altered muscular loading or through central mechanisms that tighten muscles in a myotactic unit to splint a painful joint thereby preventing further injury.<sup>11</sup>

Trigger points in the superficial masseter, lateral pterygoid, and the temporalis muscles can refer pain to the upper teeth.<sup>12-14</sup> Trigger points in these muscles are common in office workers,<sup>15</sup> such as the patient in the current case. Additionally, individuals with TMD have a higher incidence of trigger points throughout the head and neck and lower pressure pain thresholds (PPT) in the masseter and temporalis muscles than healthy controls.<sup>12,15-18</sup> Because both the masseter and temporalis contract to close the mouth, trigger points may have been activated during the check for pressure sensitivity in this patient. However, neither muscle was evaluated for trigger points in this patient because the pain was not reproduced when checking for pressure sensitivity in the adjacent teeth. If these masticatory muscles were involved in this patient's symptoms, the OMT provided would affect the muscles as well the biomechanics of the TMJ, temporal, and facial bones.

The TMJ are fibrocartilage-lined synovial joints that consist of a rounded condyle on the posterior superior aspect of the rami of the mandible that project into the articular fossae located in the temporal bones.<sup>8</sup> Between the condyle and the fossa is a fibrocartilage disc that glides in and out of the fossa during opening and closing of the mouth and provides a cushion between the 2 bony surfaces. The disc is tethered posteriorly to the temporal bone by a thick cartilaginous ligament and anteriorly to both the anterior joint capsule and the lateral pterygoid muscle.<sup>19</sup> If the disc becomes displaced, then bone-on-bone contact may occur,<sup>8</sup> leading to pain, altered range of motion, and joint destruction. The popping that occurs with mouth opening and closing is thought to be the disc being forced out of alignment.<sup>8</sup>

The patient in this case demonstrated deviation with opening and closing on physical examination, but no pain, popping, or crepitus was appreciated. Her previous TMD pain was classic in that it was unilateral and dull, localized to the TMJ, and worsened over the course of the day.<sup>1</sup> The MRI obtained 6 months after the reported visit demonstrated moderate disc degeneration with abnormal translation but no frank destruction.

*(continued on page 21)*

*(continued from page 20)*

One study found that individuals with TMJ dysfunction may experience pain associated with abnormal motion of the disc.<sup>20</sup> The disc may become anteriorly displaced, affecting the positioning of the mandibular condyle when the mouth is closed and derangement of the mandible during opening and closing. The resulting abnormal biomechanics lead to irritation and inflammation of the joint capsule and posterior attachments of the disc and ultimately to bony changes of osteoarthritis<sup>20</sup> as the body attempts to alter structure to compensate for the altered function.

Inflammation of the fibers attaching the disc to the posterior TMJ capsule are much more likely to occur in individuals with bruxism, the condition of excessive grinding or clenching of the teeth.<sup>20</sup> Enamel wear is a visible sign of bruxism since grinding opposing teeth will wear enamel from the contacting surfaces.<sup>21</sup> In addition to enamel wear, bruxism also has been associated with tooth sensitivity, altered TMJ motion, and masticatory muscle tenderness.<sup>21</sup> The patient in this case did not show obvious signs of dental enamel wear; however, not all individuals who grind their teeth demonstrate enamel wear.<sup>22</sup>

Oral appliances, such as the bite-guard prescribed for the patient in the current case, are used to treat nighttime clenching and grinding. These appliances hold the teeth a few millimeters apart and seem to decrease the electrical activity of the masticatory muscles at rest.<sup>23</sup> This phenomenon has made them useful in the management of TMD.<sup>23</sup> Amorim et al<sup>24</sup> demonstrated that the use of night splints for just 1 night reduced daytime resting and isometric electromyographic activity of the masseter muscle in sleep bruxers.

The patient in the current case was under long-term treatment for thoracic outlet syndrome related to postural dysfunction. La Touche et al<sup>25</sup> found a significant association between head posture and PPT in the masticatory muscles. Both posterior and anterior head postures were associated with lower PPT in the masticatory muscle compared with a neutral head posture.<sup>25</sup> This finding may be due to an increased excitability of the muscles when they are not in a balanced resting state.<sup>25</sup>

Slumped sitting also has been associated with increased muscle activity of the cervical erector spinae muscles.<sup>26</sup> Wright et al<sup>27</sup> found that over a 4-week period, patients who were taught exercises to treat postural dysfunction had greater improvement in TMD and neck symptoms and higher PPT than patients who received only nonsteroidal anti-inflammatory drugs (NSAIDs) and basic self-care instructions. A systematic review conducted by Brantingham et al<sup>28</sup> found that manual medicine alone or combined with other modalities such as postural exercises produced statistically signifi-

cant short-term improvements in range and quality of TMJ motion along with decreased pain and clenching.

Optimal functioning of the TMJ requires coordinated movement of the head and neck. Zafar et al<sup>29</sup> found that voluntary TMJ motion is coupled with motion at the OA joint and cervical vertebra, suggesting that dysfunction of the OA joint and cervical spine impact the biomechanics of the TMJ. This interaction is likely due to the position of the occiput affecting the mechanics of the temporal bone, with the temporal bone position affecting the TMJ biomechanics.<sup>7</sup> Internal rotation of the temporal bone and maxilla can cause deviation to the mandible to the opposite side,<sup>7</sup> as was found in this patient.

The patient in the current case also was treated for both OA joint and C2 somatic dysfunctions along with other dysfunctions of the cranial, thoracic, and rib areas. She had a marked immediate improvement in pain and pressure sensitivity of the tooth following treatment. Numerous studies have demonstrated that manual medicine interventions improve TMJ range of motion and increase PPT in the masticatory musculature. Bretschwerdt et al<sup>30</sup> assessed the PPT of the masseter and upper trapezius muscles in 120 healthy volunteers immediately before and after hamstring muscle stretching. They found that the PPT had increased in both muscles and maximal mouth opening had increased when measured 5 minutes after stretching.<sup>30</sup>

Additional studies<sup>31,32</sup> found that applying high-velocity, low-amplitude technique (HVLA) to the OA joint increased PPT immediately for both the temporalis and masseter muscles and increased maximal jaw opening. While HVLA was not used in the current case, other direct techniques, such as muscle energy and articular techniques, were used and likely had a similar effect.

Long-term studies also have shown the benefit of manual treatments for TMD. Cuccia et al<sup>33</sup> directly compared OMT to conventional conservative treatment (oral appliance, physical therapy, and directed stretching) when applied every 2 weeks. At the end of 6 months (12 treatments), both groups had made similar improvements in function, but the OMT group had significantly less NSAID usage.<sup>33</sup>

Kalamir et al<sup>34</sup> found that combining intraoral myofascial release techniques and inhibition of the sphenopalatine ganglion with a home program of jaw exercises that included self-administered muscle energy techniques resulted in less pain and increased range of motion compared with manipulation alone after 1 year. The patient in the current case was later taught jaw exercises to be per-

*(continued on page 22)*

(continued from page 21)

formed with her postural exercises. It is reasonable to assume that, when combined with OMT, she would receive maximum long-term benefit for her TMD.

## Conclusion

The current case report demonstrates the difficulty in determining the origin of undifferentiated dental pain in the absence of overt signs of infection. If this patient was suffering from an early dental abscess, the OMT directed towards optimizing vascular and lymphatic drainage and normalizing autonomic tone may have provided sufficient improvement in homeostatic mechanisms to help the patient's body heal. However, the convergence of the somatosensory nerves in the orofacial, head, and neck regions may have allowed pain associated with her TMD to refer to her tooth.

This same convergence may have provided an opportunity to improve symptoms in one area by treating somatic dysfunction in another area. In this case, optimizing structure and function of the head, cervical, thoracic, and rib regions afforded the patient rapid resolution of her dental pain and associated somatic dysfunctions. Long-term care for her postural, thoracic outlet and TMD issues will continue to include OMT in combination with a home-exercise program.

## Acknowledgments

Dr Snider originally prepared this case report to meet one of her requirements for earning fellowship in the American Academy of Osteopathy. As a consequence, this manuscript underwent 2 separate peer-review processes: The first was through the Committee on Fellowship in the American Academy of Osteopathy, and the second was through *The AAO Journal*. Dr Snider became a fellow of the AAO in March 2015 during the Academy's Convocation in Louisville, Kentucky.

## References

1. Amsterdam JT. Oral medicine. In: Marx JA, Hockberger RS, Walls RM, eds. *Rosen's Emergency Medicine: Concepts and Clinical Practice*. 8th ed. Philadelphia, PA: Saunders; 2014:895-908.
2. Christian JM. Odontogenic infections. In: Flint PW, Haughey BH, Lund VJ, et al, eds. *Cummings Otolaryngology Head and Neck Surgery*. Vol 1. 5th ed. Philadelphia, PA: Mosby; 2010:177-190.
3. Runyon MS, Brennan MT, Batts JJ, et al. Efficacy of penicillin for dental pain without overt infection. *Acad Emerg Med*. 2004;11(12):1268-1271.
4. Ellison SJ. The role of phenoxymethylpenicillin, amoxicillin, metronidazole and clindamycin in the management of acute dentoalveolar abscesses—a review. *Br Dent J*. 2009;206(7):357-362. doi: 10.1038/sj.bdj.2009.257.
5. Benko K. Dental emergencies. In: Adams JG, ed. *Emergency Medicine: Clinical Essentials*. 2nd ed. Philadelphia, PA: Saunders; 2013:236-248.
6. Graney DO, Sie KCY. Anatomy and developmental embryology of the neck. In: Flint PW, Haughey BH, Lund VJ, et al, eds. *Cummings Otolaryngology Head and Neck Surgery*. Vol 3. 5th ed. Philadelphia, PA: Mosby; 2010:2577-2586.
7. Heinking KP, Kappler RE, Ramey KA. Head and suboccipital region. In: Chila AG, ed. *Foundations of Osteopathic Medicine*. 3rd ed. Philadelphia, PA: Lippincott Williams & Wilkins; 2011:484-512.
8. Ingawale S, Goswami T. Temporomandibular joint: disorders, treatments, and biomechanics. *Ann Biomed Eng*. 2009;37(5):976-996. doi: 10.1007/s10439-009-9659-4.
9. Kojima Y. Convergence patterns of afferent information from the temporomandibular joint and masseter muscle in the trigeminal subnucleus caudalis. *Brain Res Bull*. 1990;24(4):609-616.
10. Sessle BJ, Hu JW, Amano N, Zhong G. Convergence of cutaneous, tooth pulp, visceral, neck and muscle afferents onto nociceptive and non-nociceptive neurones in trigeminal subnucleus caudalis (medullary dorsal horn) and its implications for referred pain. *Pain*. 1986;27(2):219-235.
11. Inoue E, Maekawa K, Minakuchi H, et al. The relationship between temporomandibular joint pathosis and muscle tenderness in the orofacial and neck/shoulder region. *Oral Surg Oral Med Oral Pathol Oral Radiol Endod*. 2010;109(1):86-90. doi: 10.1016/j.tripleo.2009.07.050.
12. Fernandez-de-Las-Penas C, Galan-Del-Rio F, Alonso-Blanco C, Jimenez-Garcia R, Arendt-Nielsen L, Svensson P. Referred pain from muscle trigger points in the masticatory and neck-shoulder musculature in women with temporomandibular disorders. *J Pain*. 2010;11(12):1295-1304. doi: 10.1016/j.jpain.2010.03.005.
13. Wright EF. Referred craniofacial pain patterns in patients with temporomandibular disorder. *J Am Dent Assoc*. 2000;131(9):1307-1315.
14. Simons DG, Travell JG, Simons LS. *Travell and Simons' Myofascial Pain and Dysfunction: The Trigger Point Manual*. Vol 1. 2nd ed. Philadelphia, PA: Lippincott Williams & Wilkins; 1998:331, 351.
15. Fernandez-de-las-Penas C, Grobli C, Ortega-Santiago R, et al. Referred pain from myofascial trigger points in head, neck, shoulder, and arm muscles reproduces pain symptoms in blue-collar (manual) and white-collar (office) workers. *Clin J Pain*. 2012;28(6):511-518. doi: 10.1097/AJP.0b013e31823984e2.
16. Alonso-Blanco C, Fernandez-de-Las-Penas C, de-la-Llave-Rincon AI, Zarco-Moreno P, Galan-Del-Rio F, Svensson P. Characteristics of referred muscle pain to the head from active trigger points in women with myofascial temporomandibular pain and fibromyalgia syndrome. *J Headache Pain*. 2012;13(8):625-637. doi: 10.1007/s10194-012-0477-y.
17. Andrade AV, Gomes PF, Teixeira-Salmela LF. Cervical spine alignment and hyoid bone positioning with temporomandibular disorders. *J Oral Rehabil*. 2007;34(10):767-772.
18. Gomes MB, Guimaraes JP, Guimaraes FC, Neves AC. Palpation and pressure pain threshold: reliability and validity in patients with temporomandibular disorders. *Cranio*. 2008;26(3):202-210.
19. Westesson PL, Otonari-Yamamoto M, Sano T, Okano T. Anatomy, pathology, and imaging of the temporomandibular joints. In: Som PM, Curtin HD, eds. *Head and Neck Imaging*. Vol 1. 5th ed. St. Louis, MO: Mosby; 2011:1547-1613.
20. Molina OF, dos Santos J Jr, Nelson S, Nowlin T, Mazzetto M. A clinical comparison of internal joint disorders in patients presenting

(continued on page 24)

# WALKING TOWARD HEALTH: NEW EVALUATIONS IN GAIT

July 29-31, 2016 • The Pyramids, Indianapolis

## Course Description

Edward G. Stiles, DO, FAAO, and Charles A. Beck, DO, FAAO, will present research data that support using a functional approach to treat patients for gait dysfunctions.

During the past few decades, gait concepts have evolved from using a leg-propelling model to using the trunk-driving model that Serge Gracovetsky, PhD, outlined in his book *The Spinal Engine*. Dr. Stiles suggests that combining these two models with the floating compression pelvic model and the Mitchell axes model will provide a comprehensive understanding of gait mechanics. With traditional approaches to osteopathic manipulative treatment, sacral- and innominate-related gait dysfunctions can persist. By employing the clinical approach presented in this course, physicians can be confident that their patients are walking toward health.

## Course Location

**Pyramid Three** (two buildings away from the AAO's office)  
3500 DePauw Blvd., lower level, Conference Rooms A and B  
Indianapolis, IN 46268  
(317) 879-1881, ext. 220

## Course Times and Meal Information

Friday, Saturday and Sunday from 8 a.m. to 5:30 p.m. Breakfast and lunch will be provided. Please contact the AAO's event planner with special dietary needs at (317) 879-1881, ext. 220, or [EventPlanner@academyofosteopathy.org](mailto:EventPlanner@academyofosteopathy.org).

## Continuing Medical Education

24 credits of NMM- and FP-specific AOA Category 1-A CME anticipated.

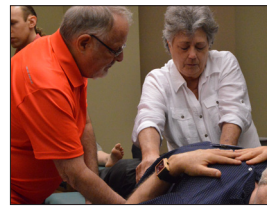## Travel Arrangements

Contact Tina Callahan of Globally Yours Travel at (800) 274-5975 or [globallyyourstravel@cox.net](mailto:globallyyourstravel@cox.net).

Registration Fees	By June 28, 2016	After June 28, 2016
Academy member in practice*	\$866	\$1,016
Member resident or intern	\$665	\$816
Student member	\$466	\$616
Nonmember practicing DO or other health care professional	\$1,066	\$1,216
Nonmember resident or intern	\$866	\$1,016
Nonmember student	\$665	\$816

\* The AAO's associate members, international affiliates and supporter members are entitled to register at the same fees as full members.

The AAO accepts check, Visa, MasterCard and Discover payments in U.S. dollars. The AAO does not accept American Express.

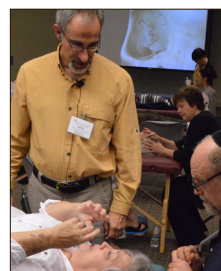

## Course Directors

A 1965 graduate of what is now the A.T. Still University–Kirksville College of Osteopathic Medicine in Missouri, **Edward G. Stiles, DO, FAAO**, has a rich and deep understanding of numerous pioneering concepts, events and personalities in osteopathic medicine.

While an osteopathic medical student, Dr. Stiles trained with George Andrew Laughlin, DO, a grandson of Andrew Taylor Still, MD, DO. Early in his medical career, Dr. Stiles took over the Cambridge, Massachusetts, practice of Perrin T. Wilson, DO, an internationally recognized osteopathic physician and the second person to lead the American Academy of Osteopathy. Dr. Stiles established the first hospital-based osteopathic manipulative treatment (OMT) service in the United States, and he helped develop the first OMT billing codes. Additionally, he has been recognized by the American Osteopathic Association as a Great Pioneer in Osteopathic Medicine.

Dr. Stiles has taught at the osteopathic medical colleges at Oklahoma State University, Michigan State University and the University of Pikeville in Kentucky. He has delivered the American Osteopathic Association's Andrew Taylor Still Memorial Address, as well as the Academy's Thomas L. Northup Lecture, its Scott Memorial Lecture and its Harold A. Blood, DO, FAAO, Memorial Lecture. Dr. Stiles also is a recipient of the Academy's highest award, the Andrew Taylor Still Medallion of Honor.



Like Dr. Stiles, **Charles A. Beck, DO, FAAO**, is board certified in neuromusculoskeletal medicine. He earned his DO degree from the University of Pikeville–Kentucky College of Osteopathic Medicine (UP-KYCOM).

Dr. Beck has received many awards, including the Edward G. Stiles Award for Osteopathic Manipulation from UP-KYCOM, and he serves as an adjunct faculty member for several osteopathic medical schools, including the Lake Erie College of Osteopathic Medicine and the Marian University College of Osteopathic Medicine. Dr. Beck is in private practice in Indianapolis at the Meridian Holistic Center.

Click here to view the [AAO's cancellation and refund policy](#).

Click here to view the [AAO's photo release statement](#).



Register online at [www.academyofosteopathy.org](http://www.academyofosteopathy.org), or contact the Academy at [EventPlanner@academyofosteopathy.org](mailto:EventPlanner@academyofosteopathy.org) or at (317) 879-1881, ext. 220.

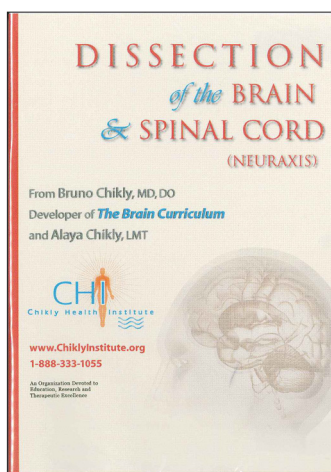


(continued from page 22)

- disk-attachment pain: prevalence, characterization, and severity of bruxing behavior. *Cranio*. 2003;21(1):17-23.
21. Yadav S. A study on prevalence of dental attrition and its relation to factors of age, gender and to the signs of TMJ dysfunction. *J Indian Prosthodont Soc*. 2011;11(2):98-105. doi: 10.1007/s13191-011-0076-7.
  22. Pergamalian A, Rudy TE, Zaki HS, Greco CM. The association between wear facets, bruxism, and severity of facial pain in patients with temporomandibular disorders. *J Prosthet Dent*. 2003;90(2):194-200.
  23. Klasser GD, Greene CS. Oral appliances in the management of temporomandibular disorders. *Oral Surg Oral Med Oral Pathol Oral Radiol Endod*. 2009;107(2):212-223. doi: 10.1016/j.tripleo.2008.10.007.
  24. Amorim CF, Giannasi LC, Ferreira LM, et al. Behavior analysis of electromyographic activity of the masseter muscle in sleep bruxers. *J Bodyw Mov Ther*. 2010;14(3):234-238. doi: 10.1016/j.jbmt.2008.12.002.
  25. La Touche R, Paris-Alemany A, von Piekartz H, Mannheimer JS, Fernandez-Carnero J, Rocabado M. The influence of cranio-cervical posture on maximal mouth opening and pressure pain threshold in patients with myofascial temporomandibular pain disorders. *Clin J Pain*. 2011;27(1):48-55. doi: 10.1097/AJP.0b013e3181edc157.
  26. Caneiro JB, O'Sullivan P, Burnett A, et al. The influence of different sitting postures on head/neck posture and muscle activity. *Man Ther*. 2010;15(1):54-60. doi: 10.1016/j.math.2009.06.002.
  27. Wright EF, Domenech MA, Fischer JR, Jr. Usefulness of posture training for patients with temporomandibular disorders. *J Am Dent Assoc*. 2000;131(2):202-210.
  28. Brantingham JW, Cassa TK, Bonnefin D, et al. Manipulative and multimodal therapy for upper extremity and temporomandibular disorders: a systematic review. *J Manipulative Physiol Ther*. 2013;36(3):143-201. doi: 10.1016/j.jmpt.2013.04.001.
  29. Zafar H, Nordh E, Eriksson PO. Temporal coordination between mandibular and head-neck movements during jaw opening-closing tasks in man. *Arch Oral Biol*. 2000;45(8):675-682.
  30. Bretschwerdt C, Rivas-Cano L, Palomeque-del-Cerro L, Fernandez-de-las-Penas C, Albuquerque-Sendin F. Immediate effects of hamstring muscle stretching on pressure pain sensitivity and active mouth opening in healthy subjects. *J Manipulative Physiol Ther*. 2010;33(1):42-47. doi: 10.1016/j.jmpt.2009.11.009.
  31. Mansilla-Ferragut P, Fernandez-de-Las Penas C, Albuquerque-Sendin F, Cleland JA, Bosca-Gandia JJ. Immediate effects of atlanto-occipital joint manipulation on active mouth opening and pressure pain sensitivity in women with mechanical neck pain. *J Manipulative Physiol Ther*. 2009;32(2):101-106. doi: 10.1016/j.jmpt.2008.12.003.
  32. Oliveira-Campelo NM, Rubens-Rebelatto J, Martin-Vallejo FJ, Albuquerque-Sendi NF, Fernandez-de-Las-Penas C. The immediate effects of atlanto-occipital joint manipulation and suboccipital muscle inhibition technique on active mouth opening and pressure pain sensitivity over latent myofascial trigger points in the masticatory muscles. *J Orthop Sports Phys Ther*. 2010;40(5):310-317. doi: 10.2519/jospt.2010.3257.
  33. Cuccia AM, Caradonna C, Annunziata V, Caradonna D. Osteopathic manual therapy versus conventional conservative therapy in the treatment of temporomandibular disorders: a randomized controlled trial. *J Bodyw Mov Ther*. 2010;14(2):179-184. doi: 10.1016/j.jbmt.2009.08.002.
  34. Kalamir A, Bonello R, Graham P, Vitiello AL, Pollard H. Intraoral myofascial therapy for chronic myogenous temporomandibular disorder: a randomized controlled trial. *J Manipulative Physiol Ther*. 2012;35(1):26-37. doi: 10.1016/j.jmpt.2011.09.004. ■

## Dissection of the Brain & Spinal Cord (Neuraxis)

Bruno J. Chikly, MD, DO (France), and Alaya Chikly, LMT



In the DVD *Dissection of the Brain and Spinal Cord (Neuraxis)*, Bruno J. Chikly, MD, DO (France), and Alaya Chikly, LMT, present a detailed and explicit evaluation of the specific structures of the central nervous system. They start by helping viewers to orient themselves to a brain model before shifting to a systematic explanation of each dissection cut. Each structure is carefully labeled with English and Latin anatomical terminology. The 14 chapters of this DVD are an amazing introduction to the complex structures and terminology of neuroscience.

Dr. Chikly is a graduate of the medical school at St. Antoine Hospital in Paris. A registered osteopath in France, Dr. Chikly received an honorary DO degree from the European School of Osteopathy in Maidstone, Kent, in the United Kingdom and a doctoral degree in osteopathy from the Royal University Libre of Brussels in Belgium.

Alaya Chikly, LMT, is the developer of Heart Centered Therapy, an approach that addresses the emotional component of disease.

1 hour, 38 minutes; \$85

10% discounts for AAO members • [www.academyofosteopathy.org](http://www.academyofosteopathy.org)



## CONTINUING MEDICAL EDUCATION

This CME Certification of Home Study is intended to document your review of the CME article in this issue of *The AAO Journal* under the criteria for AOA Category 2-B continuing medical education credit.

### CME Certification of Home Study

This is to certify that I, \_\_\_\_\_,  
(type or print name)

read the following article for AOA CME credit.

**Name of article:** “The Use of Osteopathic Manipulative Treatment for Acute Dental Pain: A Case Report”

**Authors:** Karen Teten Snider, DO, FAAO

**Publication:** *The AAO Journal*, Vol. 26, No. 1, March 2016, pages 17-24

AOA Category 2-B credit may be granted for this article.

00 \_\_\_\_\_  
(AOA number)

Full name: \_\_\_\_\_  
(type or print name)

Street address: \_\_\_\_\_

City: \_\_\_\_\_

State and ZIP code: \_\_\_\_\_

Signature: \_\_\_\_\_

Complete the quiz to the right by circling the correct answers. Send your completed answer sheet to the American Academy of Osteopathy by May 31, 2016. The AAO will forward your results to the American Osteopathic Association. You must answer 75% of the quiz questions correctly to receive CME credit.

Send this page to:  
American Academy of Osteopathy  
3500 DePauw Blvd, Suite 1100  
Indianapolis, IN 46268-1136  
LGood@academyofosteopathy.org  
Fax (317) 879-0563

1. Dental pain was the patient’s primary reason for her visit.
  - a. True
  - b. False
2. Which of the following did the patient also report?
  - a. Headache
  - b. Back pain
  - c. Shoulder pain
  - d. All of the above
3. Which of the following was not applied to the cervical area?
  - a. Articular technique
  - b. Myofascial release
  - c. High-velocity, low-amplitude thrust
  - d. Still technique
4. Which of the following are conventional treatments for dental abscesses according to the article?
  - a. Drainage and irrigation
  - b. Saline oral rinse
  - c. Antibiotics
  - d. All of the above

Below are the answers to *The AAO Journal’s* [December 2016 quiz](#) on the article titled “Effect of Select Osteopathic Manipulative Treatment Techniques on Patients With Acute Rhinosinusitis” by Yumie Nishida, DO; Mason M. Sopchak, DO; Matthew R. Jackson, DO; Theresa R. Andersoning, DO; Eric P. Leikert, DO; Stephen I. Goldman, DO, FAAO, FAOASM; and Robert W. Jarski, PhD.

1. **a.** Thick, purulent or discolored nasal discharge is a sensitive sign of sinusitis.
2. **e.** All of the symptoms listed are among the 10 measured by the 5-point Sino-Nasal Outcome Test.
3. **a.** The pilot study demonstrated no statistically significant difference between the study groups.
4. **d.** Ear pressure showed the most improvement pre- and post-treatment on day 1.

Answers to the *AAOJ’s* March 2016 CME quiz will appear in the next issue.




**March 22–26, 2017**

**“The Balance Point:  
Bringing the Science and Art of Osteopathic Medicine Together”**

**Natalie Ann Nevins, DO, program chair**

**The Broadmoor • Colorado Springs, Colorado**



# AAOJ Submission Checklist

## Manuscript Submission

- Submission emailed to [editoraaoj@gmail.com](mailto:editoraaoj@gmail.com) or mailed on a flash drive or CD to the *AAOJ* managing editor, American Academy of Osteopathy, 3500 DePauw Blvd, Suite 1100, Indianapolis, IN 46268-1136
- Manuscript formatted in Microsoft Word for Windows (.doc, .docx), text document format (.txt), or rich text format (.rtf)

## Manuscript Components

- Cover letter addressed to the *AAOJ*'s scientific editor with any special requests (eg, rapid review) noted and justified
- Title page, including the authors' full names, financial and other affiliations, and disclosure of financial support related to the original research or other scholarly endeavor described in the manuscript
- "Abstract" (see "Abstract" section in "[AAOJ Instructions for Contributors](#)" for additional information)
- "Methods" section
  - the name of the public registry in which the trial is listed, if applicable
  - ethical standards, therapeutic agents or devices, and statistical methods defined
- Four multiple-choice questions for the continuing medical education quiz and brief discussions of the correct answers
- Editorial conventions adhered to
  - terms related to osteopathic medicine used in accordance with the *Glossary of Osteopathic Terminology*
  - units of measure given with all laboratory values
  - on first mention, all abbreviations other than measurements placed in parentheses after the full names of the terms, as in "American Academy of Osteopathy (AAO)"
- Numbered references, tables, and figures cited sequentially in the text
  - journal articles and other material cited in the "References" section follow the guidelines described in the most current edition of the *AMA Manual of Style: A Guide for Authors and Editors*
  - references include direct, open-access URLs to posted, full-text versions of the documents, preferably to digital object identifiers (DOIs) or to the original sources, as in <http://digital.turn-page.com/i/576658-september-2015/18>
  - photocopies provided for referenced documents not accessible through URLs

- "Acknowledgments" section with a concise, comprehensive list of the contributions made by individuals who do not merit authorship credit, as well as permission from each individual to be named
- For manuscripts based on survey data, a copy of the original validated survey and cover letter

## Graphic Elements

- Graphics formatted as specified in the "Graphic Elements" section of "[AAOJ Instructions for Contributors](#)"
- Graphics as separate graphic files (eg, jpg, tiff, pdf), not included with text
- Each graphic element cited in numerical order (eg, *Table 1*, *Table 2* and *Figure 1*, *Figure 2*) with corresponding numerical captions provided in the manuscript
- For reprinted or adapted tables, figures, and illustrations, a full bibliographic citation given, providing appropriate attribution

## Required Legal Documentation

- For reprinted or adapted tables, figures, and illustrations, copyright holders' permission to reprint in the *AAOJ*'s online and print versions, accompanied by photocopies of the original published graphic designs
- For photographs in which patients are featured, signed and dated patient model release forms
- For named sources of unpublished data and individuals listed in the "Acknowledgments" section, written permission to publish their names in the *AAOJ*
- For authors serving in the US military, the armed forces' written approval of the manuscript, as well as military or other institutional disclaimers

## Financial Disclosure and Conflict of Interest

Authors are required to disclose all financial and nonfinancial relationships related to the submission's subject matter. All disclosures should be included in the manuscript's title page. See the "Title Page" section of "[AAOJ Instructions to Contributors](#)" for examples of relationships and affiliations that must be disclosed. Those authors who have no financial or other relationships to disclose must indicate that on the manuscript's title page (eg, "Dr Jones has no conflict of interest or financial disclosure relevant to the topic of the submitted manuscript").

## Publication in the *JAOA*

Please include permission to forward the manuscript to *The Journal of the American Osteopathic Association* if the *AAOJ*'s scientific editor determines that the manuscript would likely benefit osteopathic medicine more if the *JAOA* agreed to publish it.

Questions? Contact [editoraaoj@gmail.com](mailto:editoraaoj@gmail.com).

# Component Societies and Affiliated Organizations Calendar of Upcoming Events

**April 13-17, 2016**

Arizona Osteopathic Medical Association  
**94th annual convention: We Are Family**  
Hilton Scottsdale Resort & Villas in Arizona  
35.0 credits of AOA Category 1-A CME anticipated  
Learn more and register at [www.az-osteo.org](http://www.az-osteo.org).

**April 15-17, 2016**

The Osteopathic Cranial Academy  
**Introduction to Dr. Fulford's Philosophy  
of Life and Basic Percussion Course**  
Course director: Paula L. Eschtruth, DO, FCA  
Doubletree Portland in Oregon  
20 credits of AOA Category 1-A CME anticipated.  
Learn more and register at [www.cranialacademy.org](http://www.cranialacademy.org).

**April 15-19, 2016**

Michigan State University College of Osteopathic Medicine  
**Muscle Energy: Part I**  
Course director: Carl W. Steele, DO, PT  
Course faculty: Edward Isaacs, MD,  
and Mark Bookhout, MS, PT  
East Lansing, Michigan  
34 credits of AOA Category 1-A CME anticipated  
Learn more and register at [com.msu.edu](http://com.msu.edu).

**April 22-24, 2016**

Rocky Mountain American Academy of Osteopathy  
**Introduction to Visceral Manipulation**  
Course directors: Adrienne Marie Kania, DO,  
and Dana Christopher Anglund, DO  
Rocky Vista University College of Osteopathic Medicine  
Parker, Colorado  
20 credits of AOA Category 1-A CME anticipated  
Learn more and register  
at [rockymountainao.wix.com/rockymtnao](http://rockymountainao.wix.com/rockymtnao).

**May 2-6, 2016**

Rocky Mountain American Academy of Osteopathy  
**Introduction to Osteopathy in the Cranial Field**  
Course director: Adrienne Marie Kania, DO  
Rocky Vista University College of Osteopathic Medicine  
Parker, Colorado  
40 credits of AOA Category 1-A CME anticipated  
Learn more and register  
at [rockymountainao.wix.com/rockymtnao](http://rockymountainao.wix.com/rockymtnao).

**May 6-8, 2016**

Osteopathy's Promise to Children  
**Intermediate cranial course:**  
**Expanding the Osteopathic Concept Into the Cranial Field**  
Course director: Raymond J. Hrubby, DO, MS, FAAODist  
Osteopathic Center, San Diego  
40 credits of AOA Category 1-A CME anticipated  
Learn more and register at [www.the-promise.org](http://www.the-promise.org).

**May 11, 2016**

American Osteopathic Association  
of Prolotherapy Regenerative Medicine  
**Pre-conference: Mesotherapy**  
Course director: Aline G. Fournier, DO  
Rancho Bernardo Inn, San Diego  
8 credits of AOA Category 1-A CME anticipated  
Learn more and register at [www.prolotherapycollege.org](http://www.prolotherapycollege.org).

**May 11, 2016**

American Osteopathic Association  
of Prolotherapy Regenerative Medicine  
**Pre-Conference: Nutrition, Lies and Hormones**  
Course director: Lisa Everett Anderson,  
BSc Pharm, FACA, CCN  
Rancho Bernardo Inn, San Diego, California  
8 credits of AOA Category 1-A CME anticipated  
Learn more and register at [www.prolotherapycollege.org](http://www.prolotherapycollege.org).

**May 12-15, 2016**

American Osteopathic Association  
of Prolotherapy Regenerative Medicine  
**Spring 2016 Training Seminar—Prolotherapy and Cadaver  
Conference: Advancing the Art of Prolotherapy**  
Program chair: Arden Bruce Andersen, DO  
Rancho Bernardo Inn, San Diego, California  
27 credits of AOA Category 1-A CME anticipated  
Learn more and register at [www.prolotherapycollege.org](http://www.prolotherapycollege.org).

**June 9-13, 2016**

Sutherland Cranial Teaching Foundation  
**Osteopathy in the Cranial Field**  
Course director: Daniel B. Moore, DO  
Marian University College of Osteopathic Medicine  
Indianapolis  
40 credits of AOA Category 1-A CME anticipated  
Learn more and register at [www.sctf.com](http://www.sctf.com).